


The Use of Trans Mucosal Abutments- TMA™ Restoration

Dr. German Sierra, Colombia

Dr. Shyam Mahajan, India

Case Studies

VOL. 2 | July 2013



Immediate Loading Rehabilitation Using the All-on-Four Concept with TMA™ - Multi Unit | Dr. German Sierra , Colombia

A 60 year old patient with an edentulous maxilla with horizontal and vertical bone atrophy and a bilateral severe pneumatosis of maxillary sinuses.

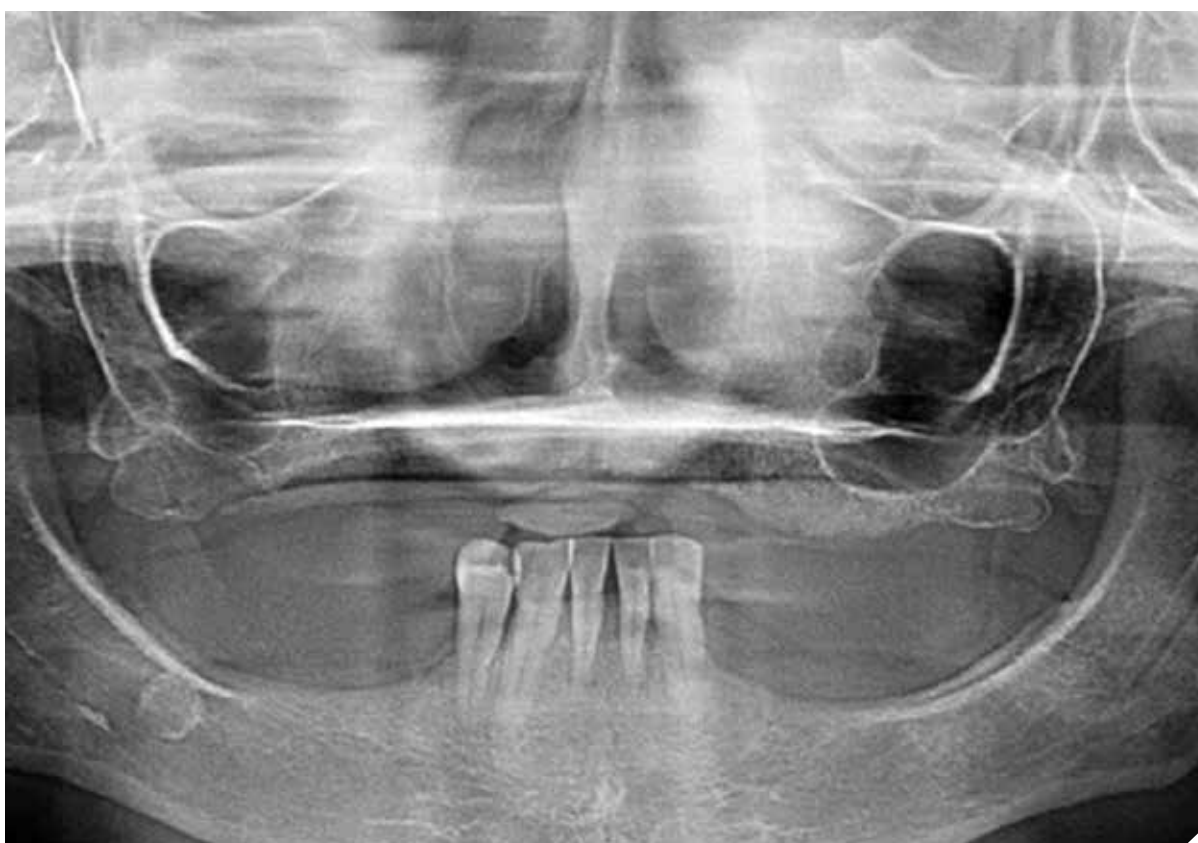An immediate loading hybrid prostheses with Co-Cr bar and acrylic was installed on four Adin Touareg™-S implants using the All-on-Four concept 24 hours after the implantation.

Adin Implants used:

Tilted implants: Touareg™-S 3.75mmD x 16mmL with Angled Trans Mucosal Abutment 30° 4.0mm - Multi Unit

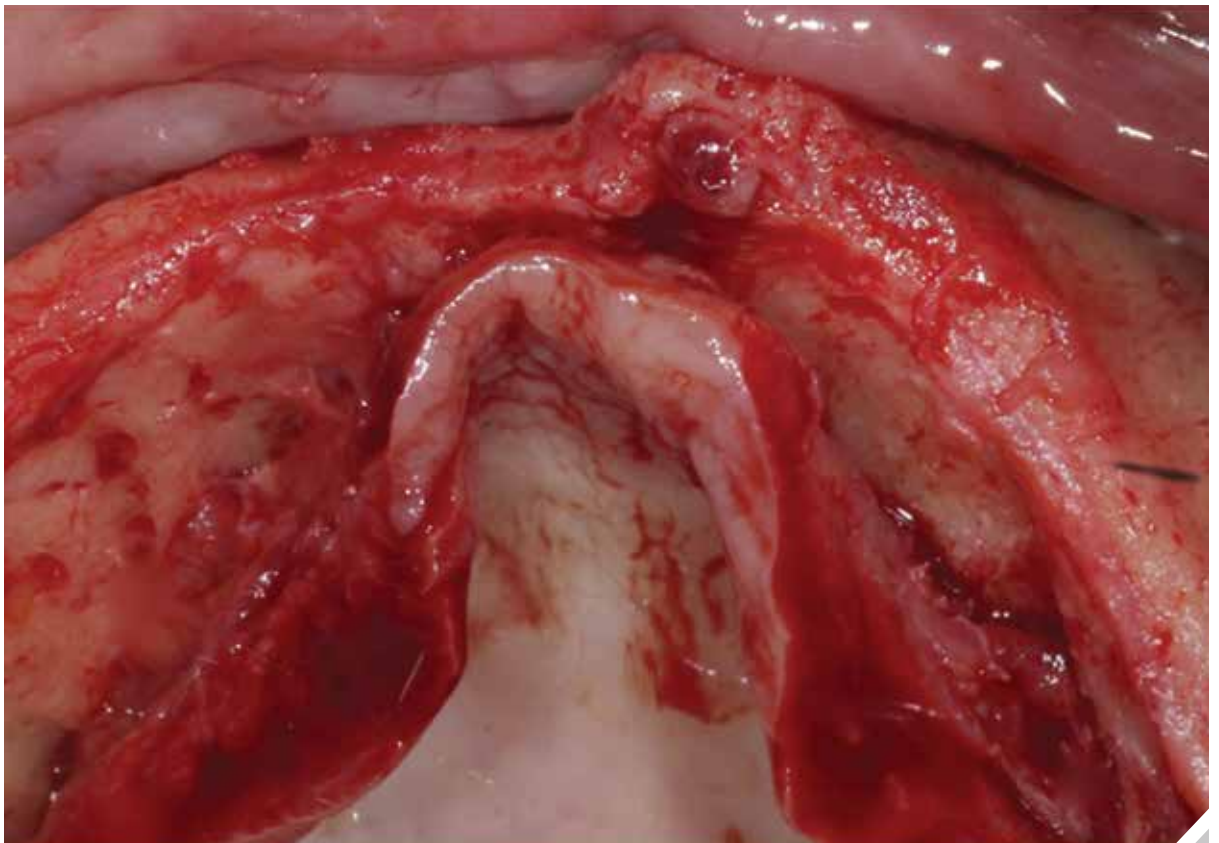
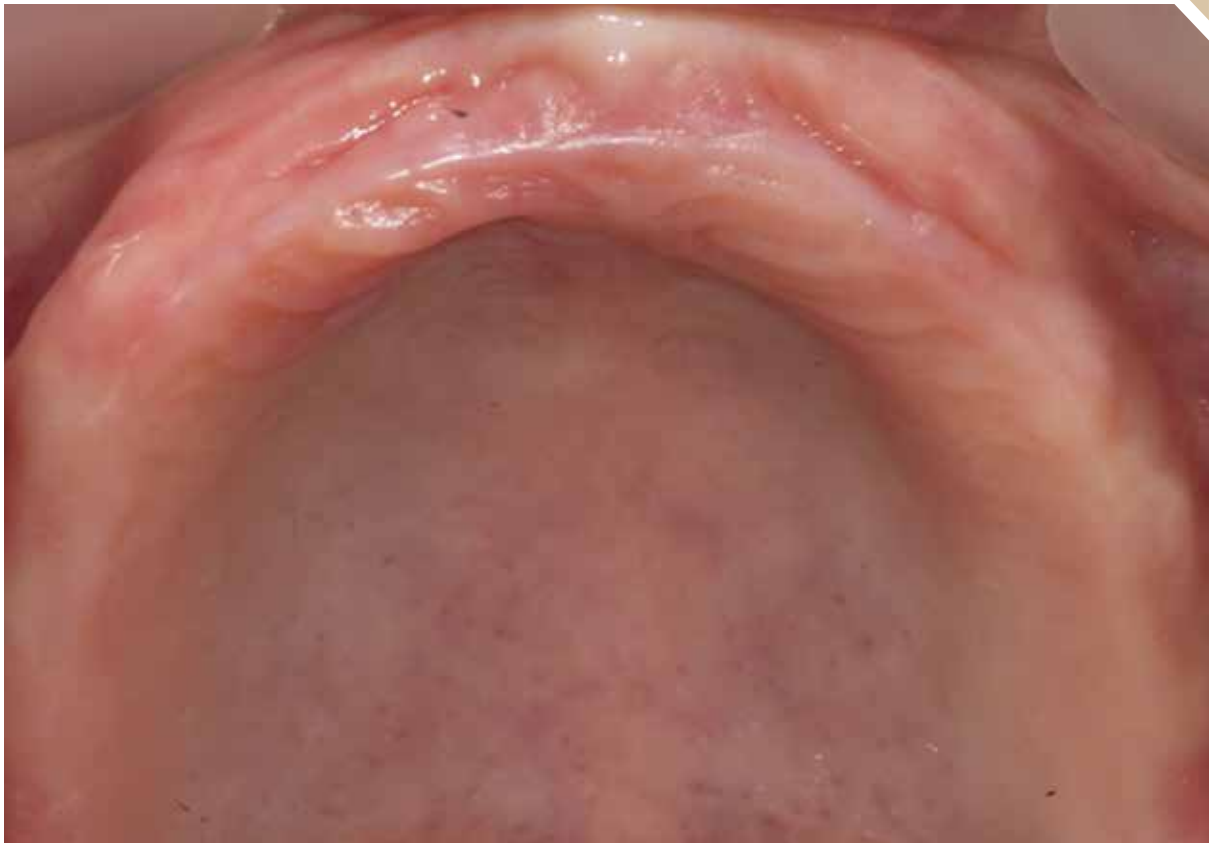Straight implants: Touareg™-S 3.75mmD x 10mmL with Straight Trans Mucosal Abutment 2mm - Multi Unit

Case 1



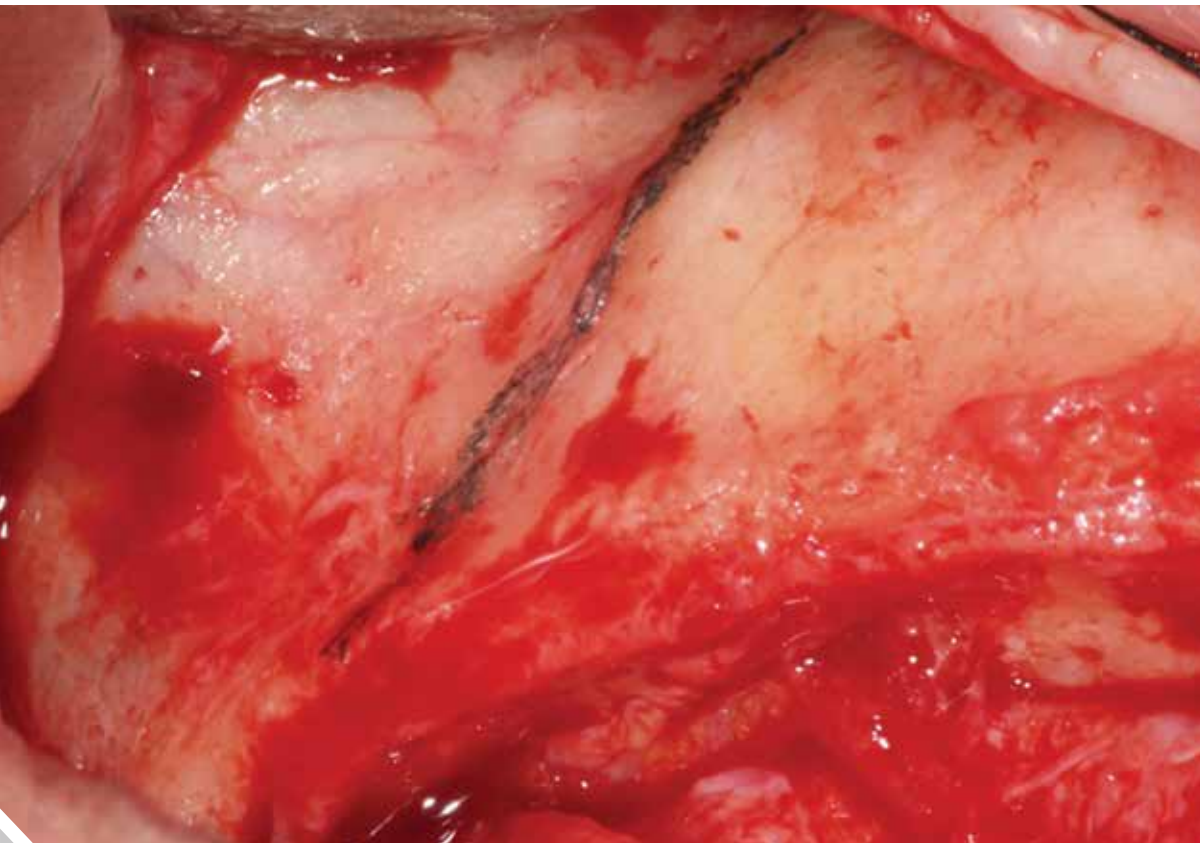
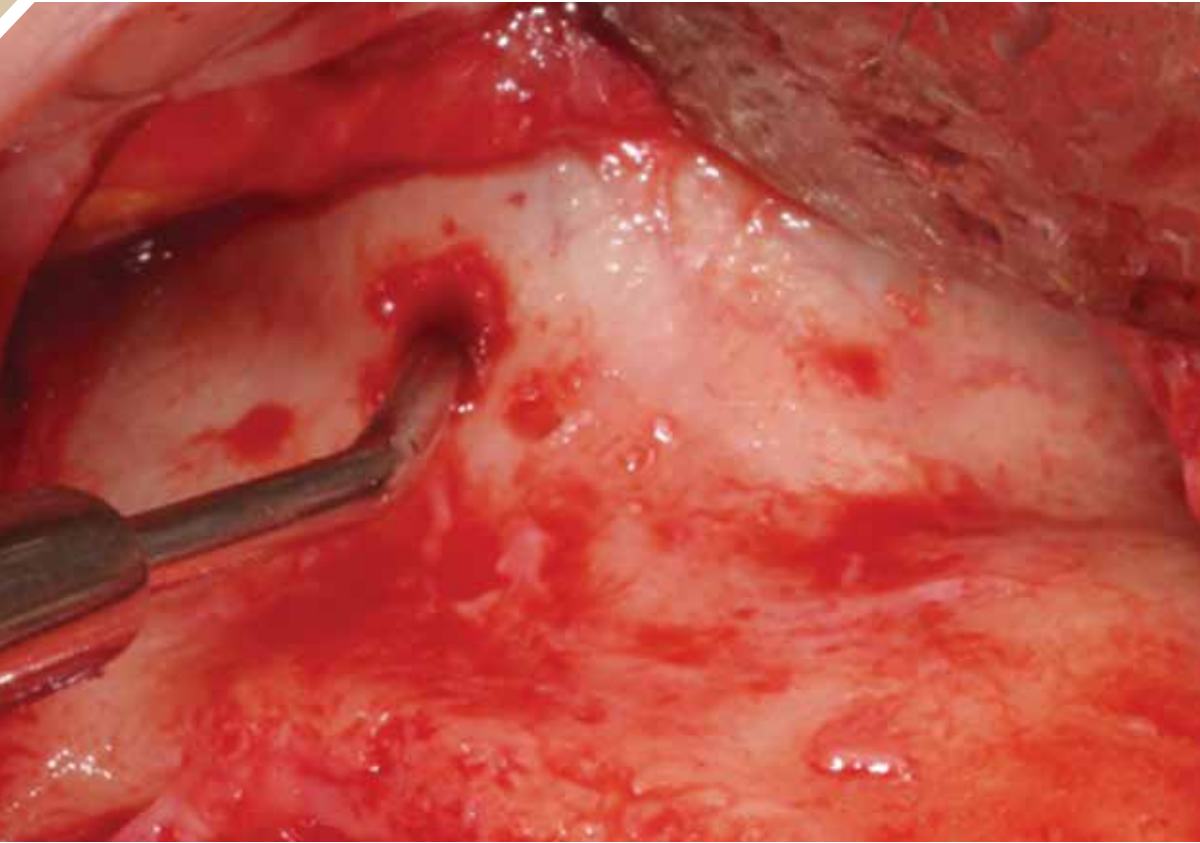
Initial
X-ray

Maxilla Edentulous
Patient



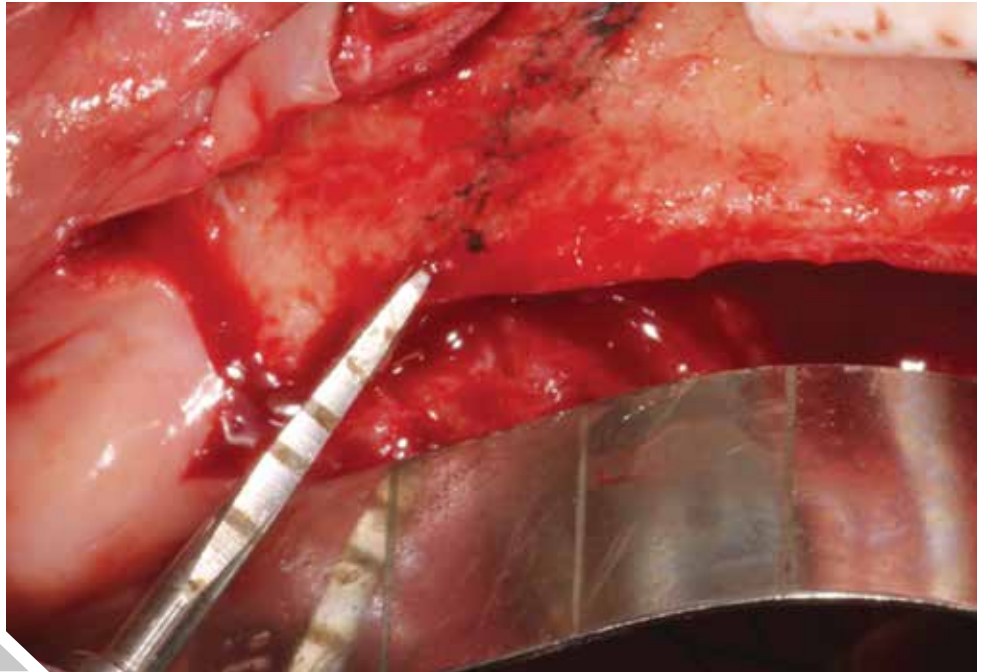
Bone Exposure

Sinus
Exposure

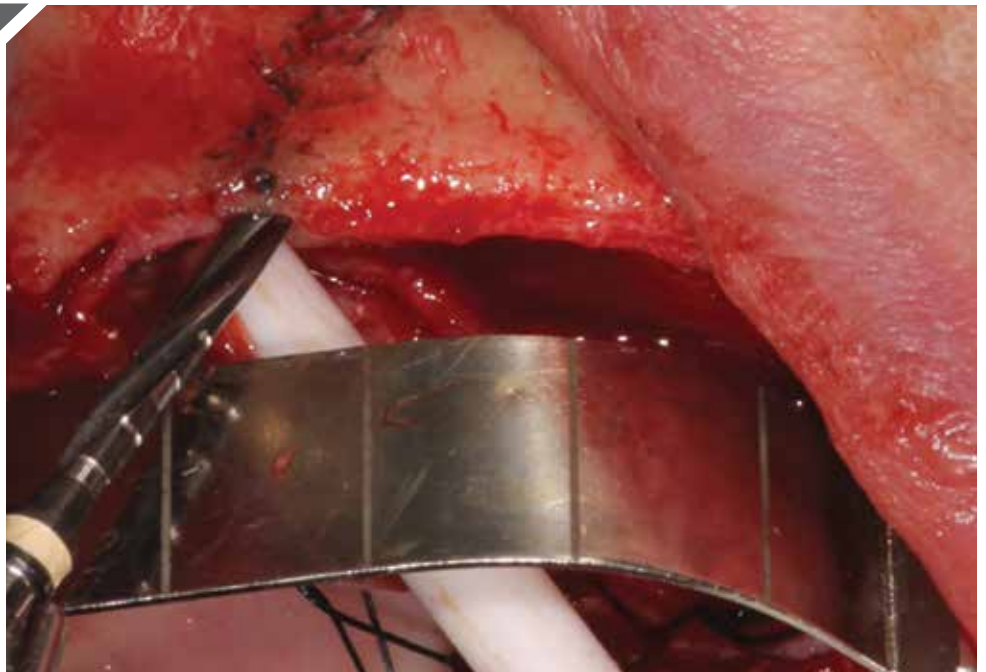


Anterior
Sinus Wall

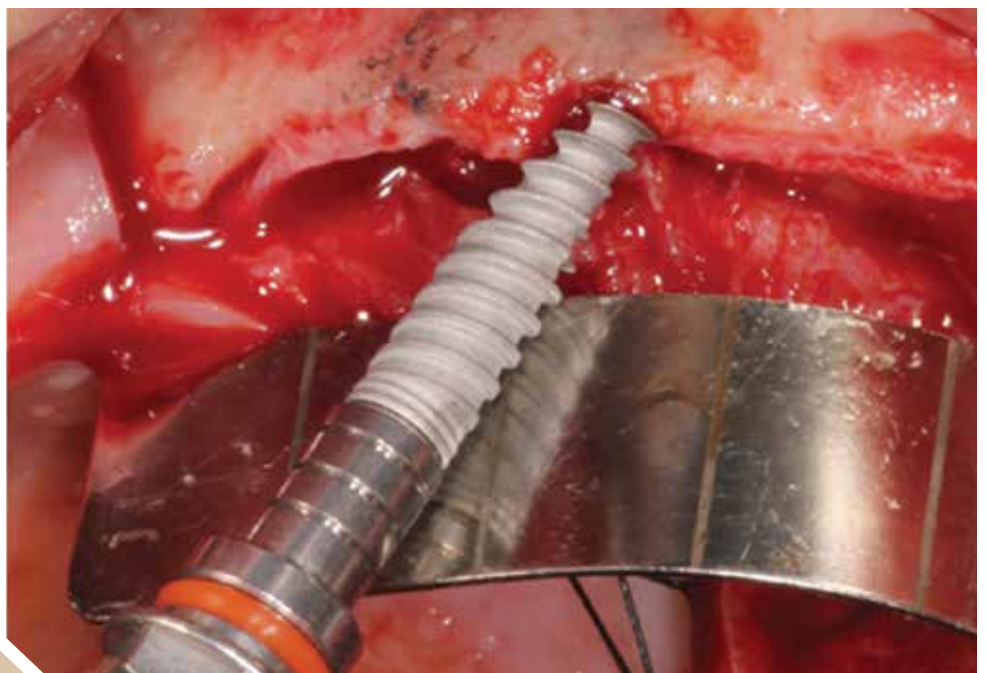
Initial
Drilling 30°



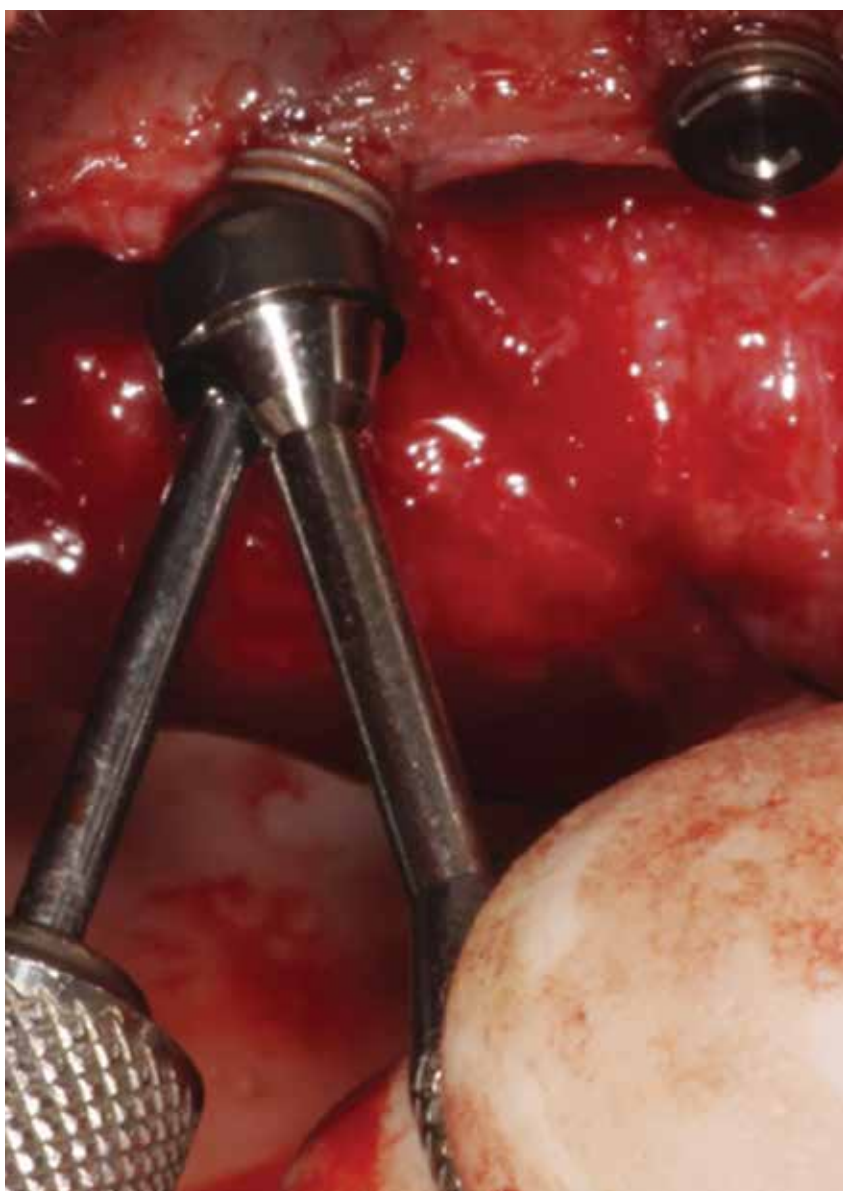
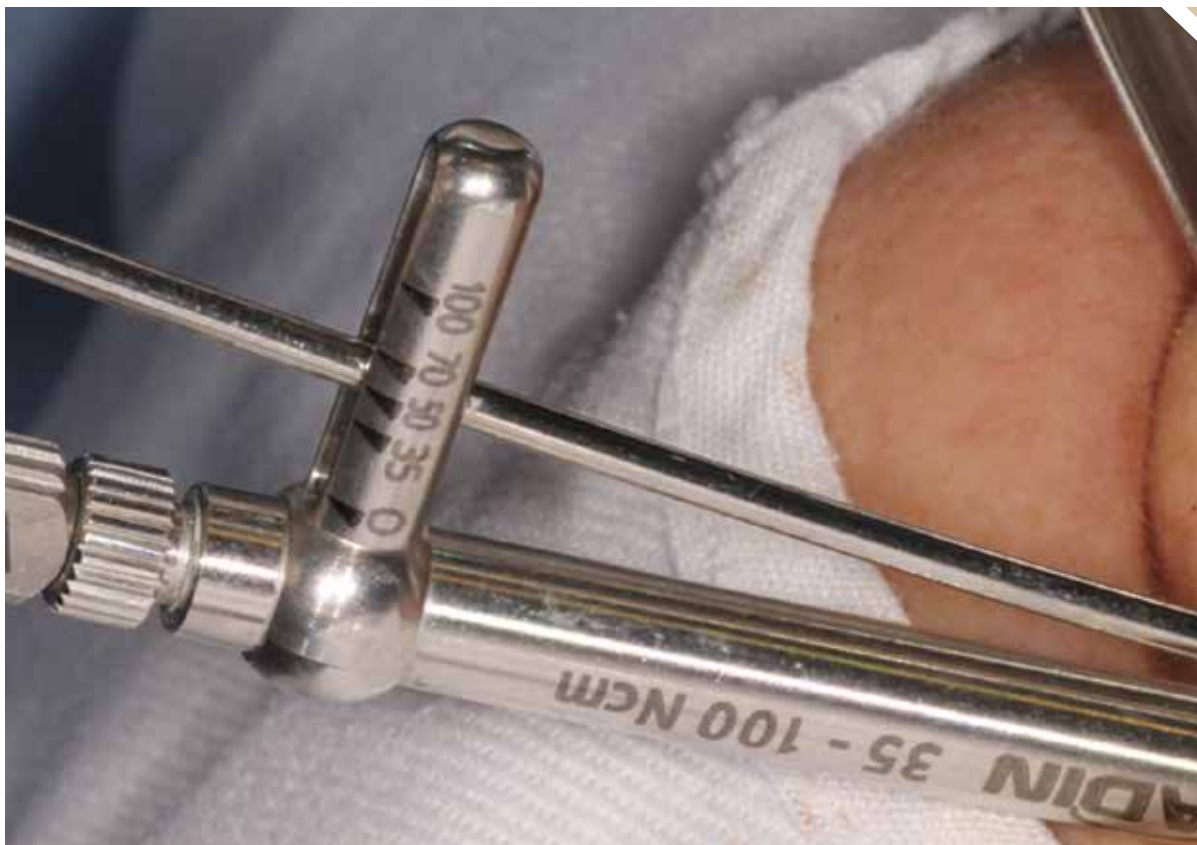Final
Drilling 30°



Implant
Insertion 30°

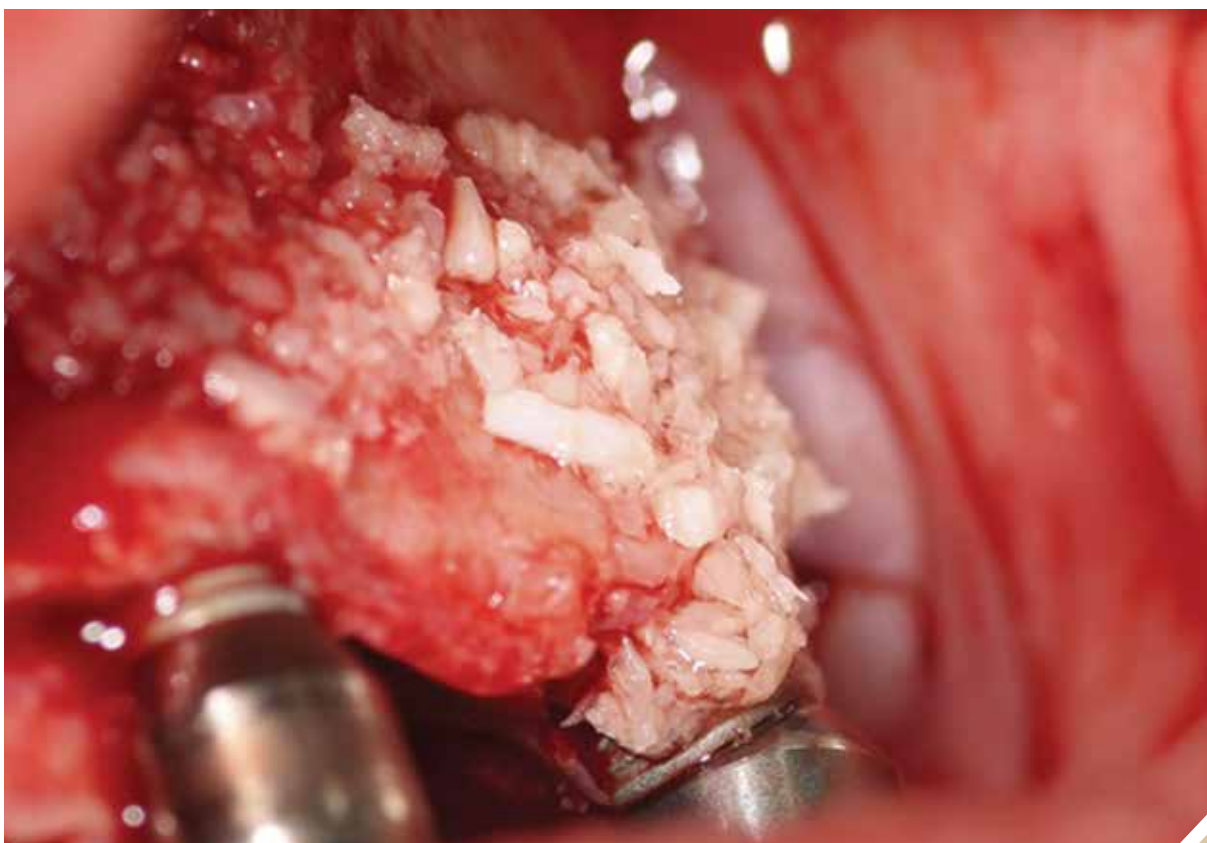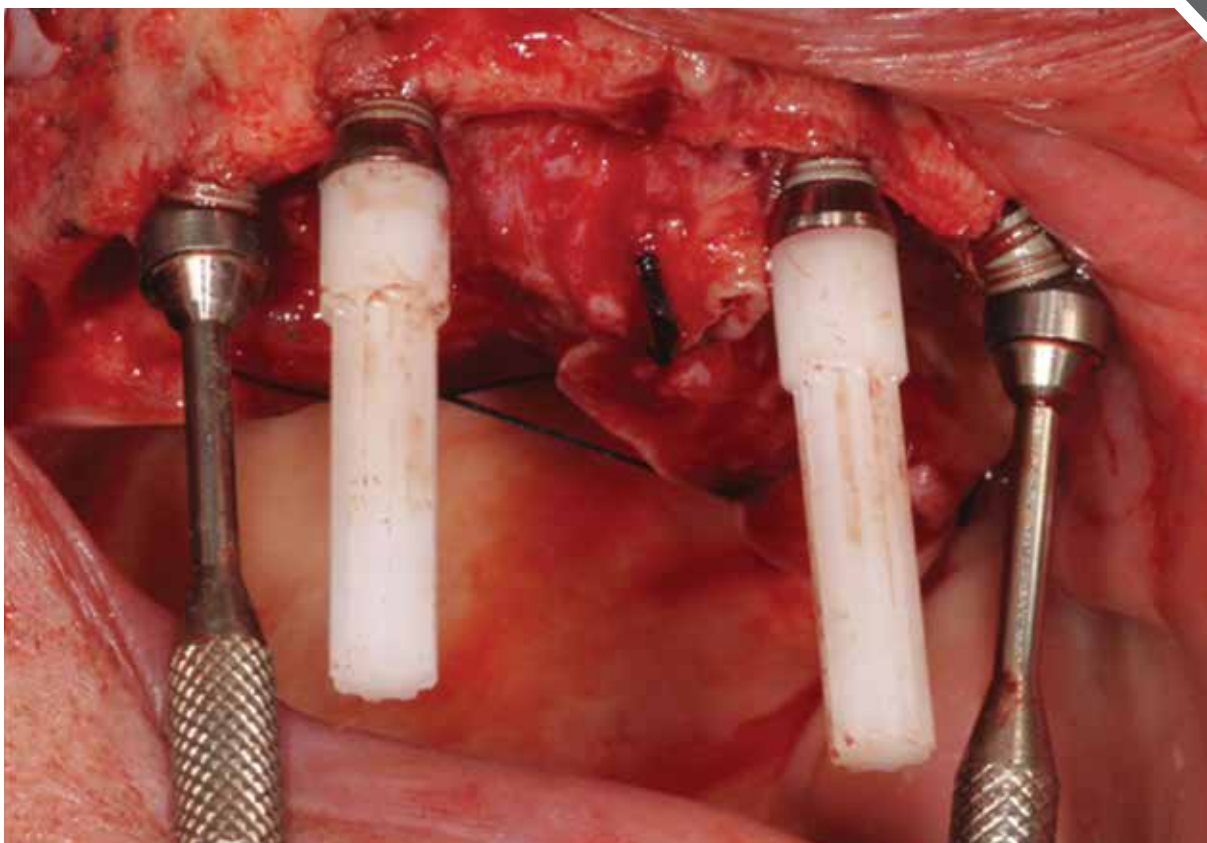


70 Ncm
Torque



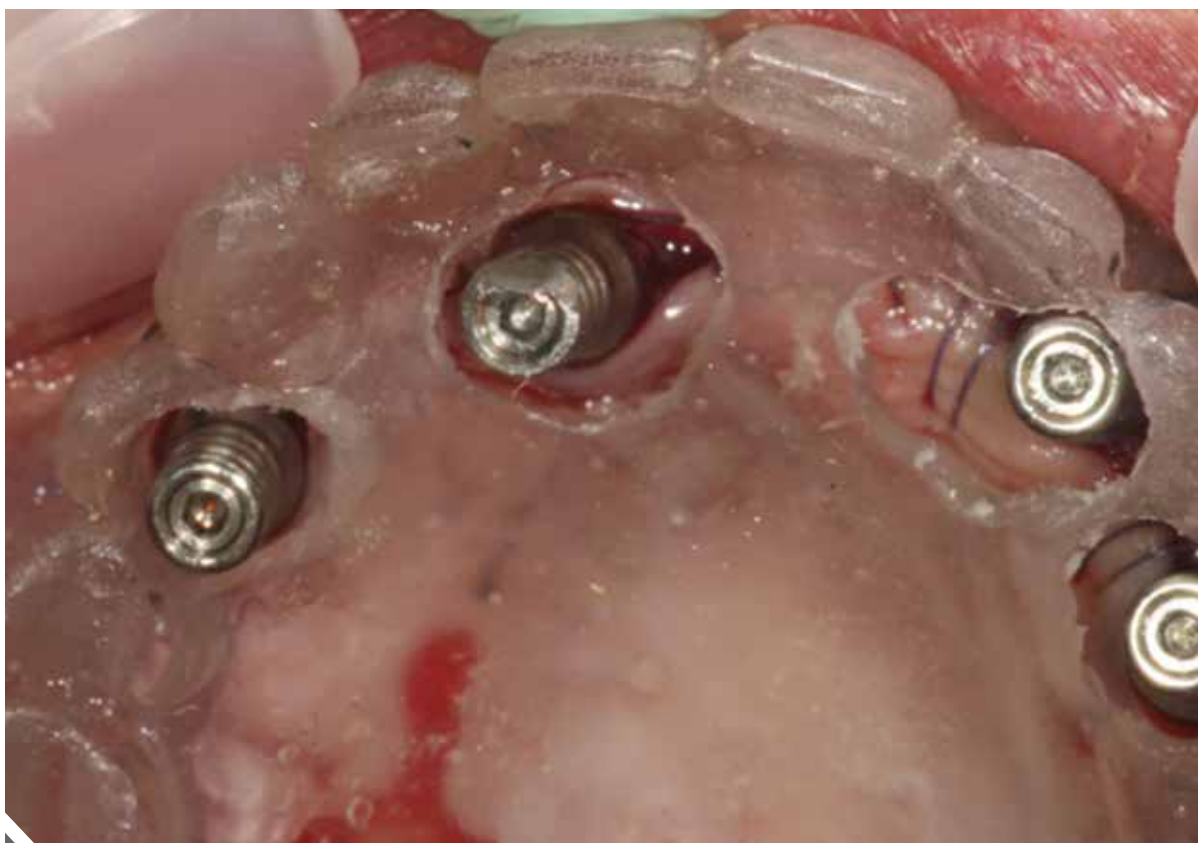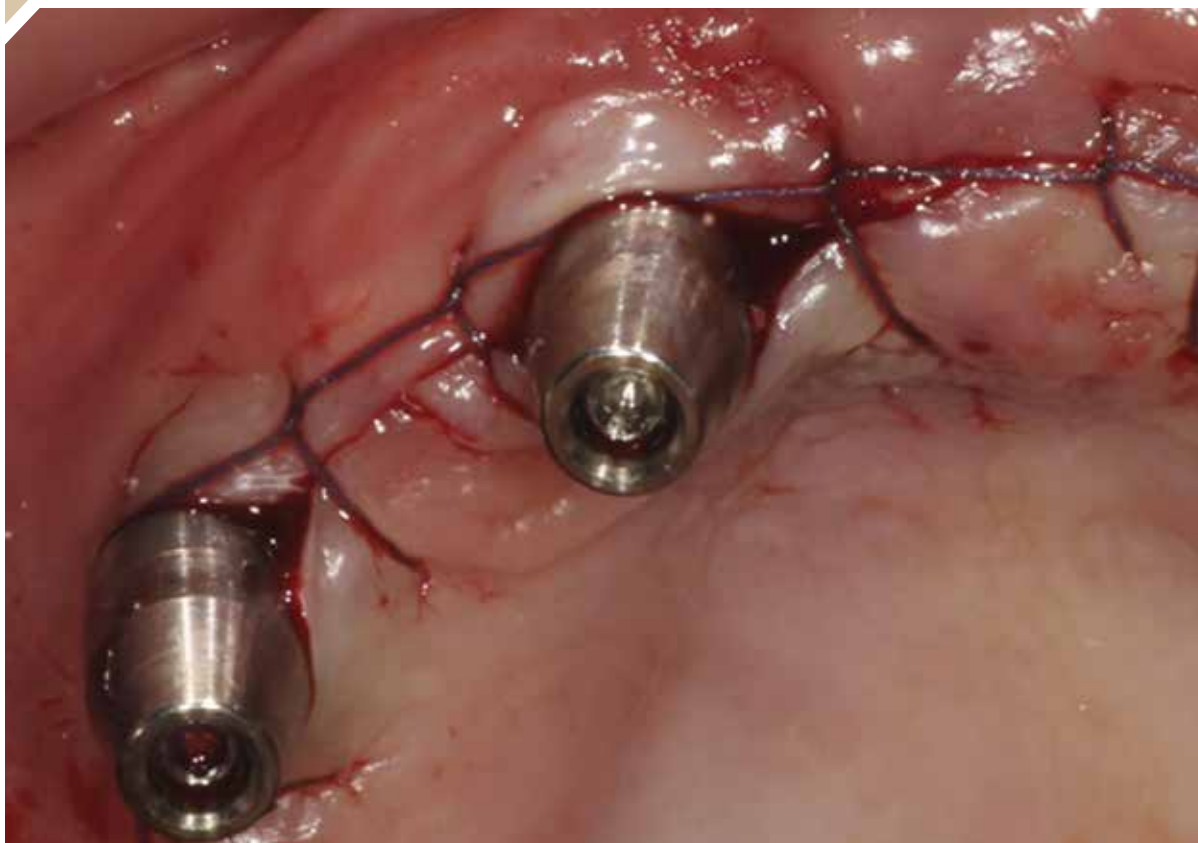
Placement of Adin's TMA™ -
Multi Unit Abutment 30°

Two 30° and Two
Straigh TMA™ –
Multi Unit Abutments



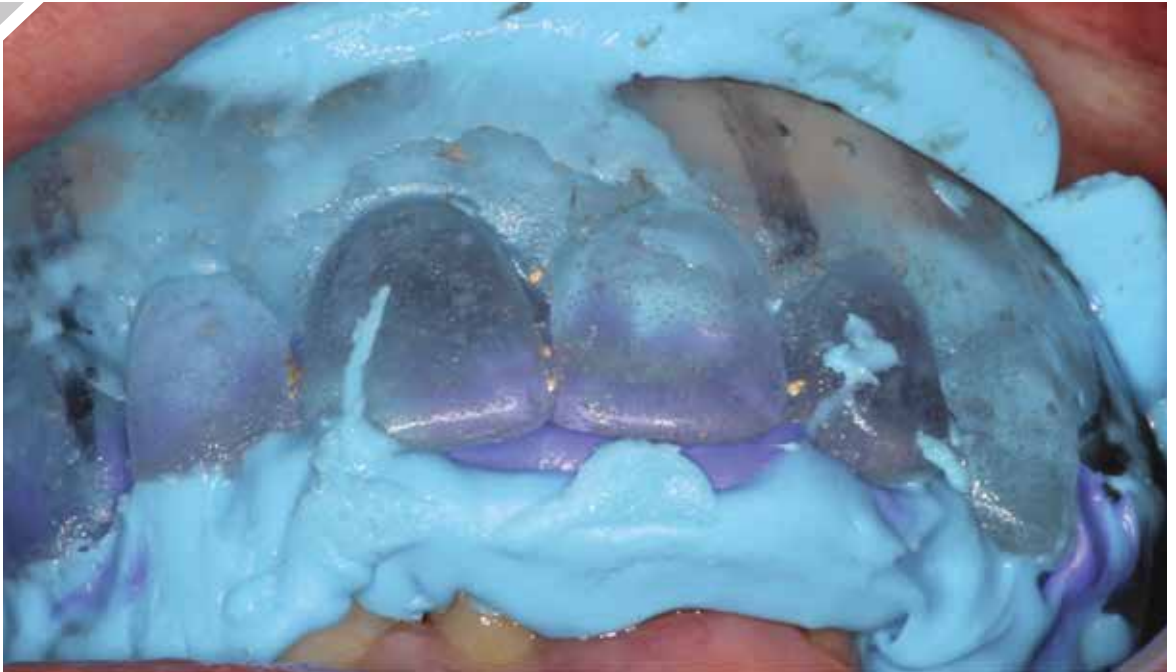
DFDB Placement

TMA™ Healing Cap
While Sutures

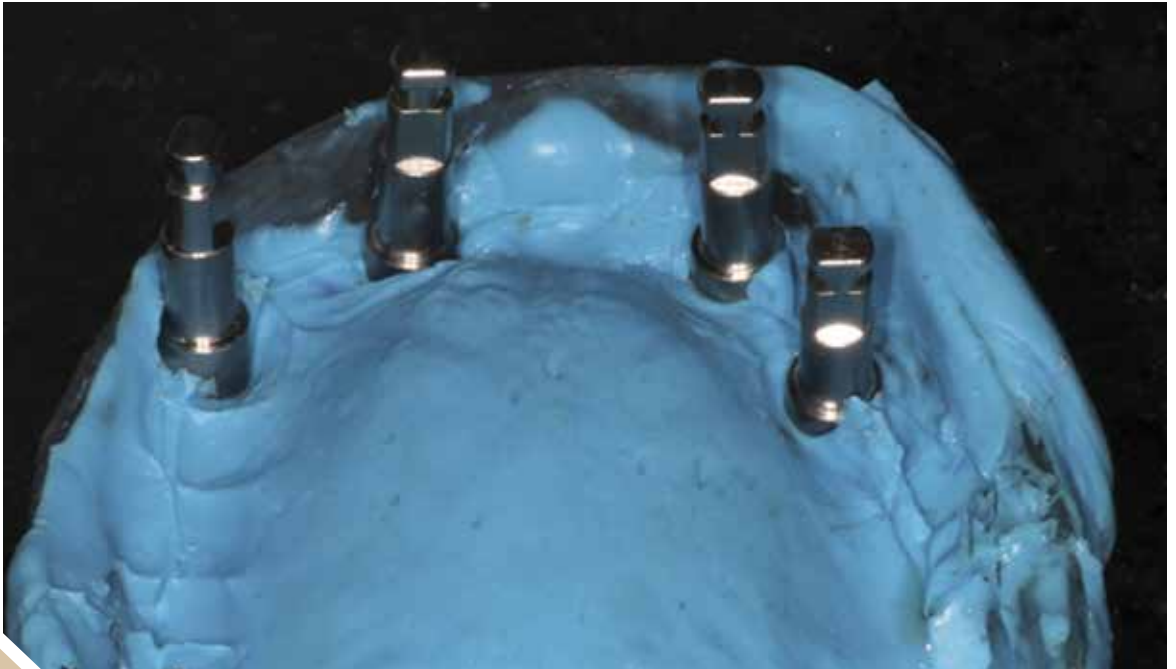


TMA™ Closed Tray
Transfers with
Denture Duplication

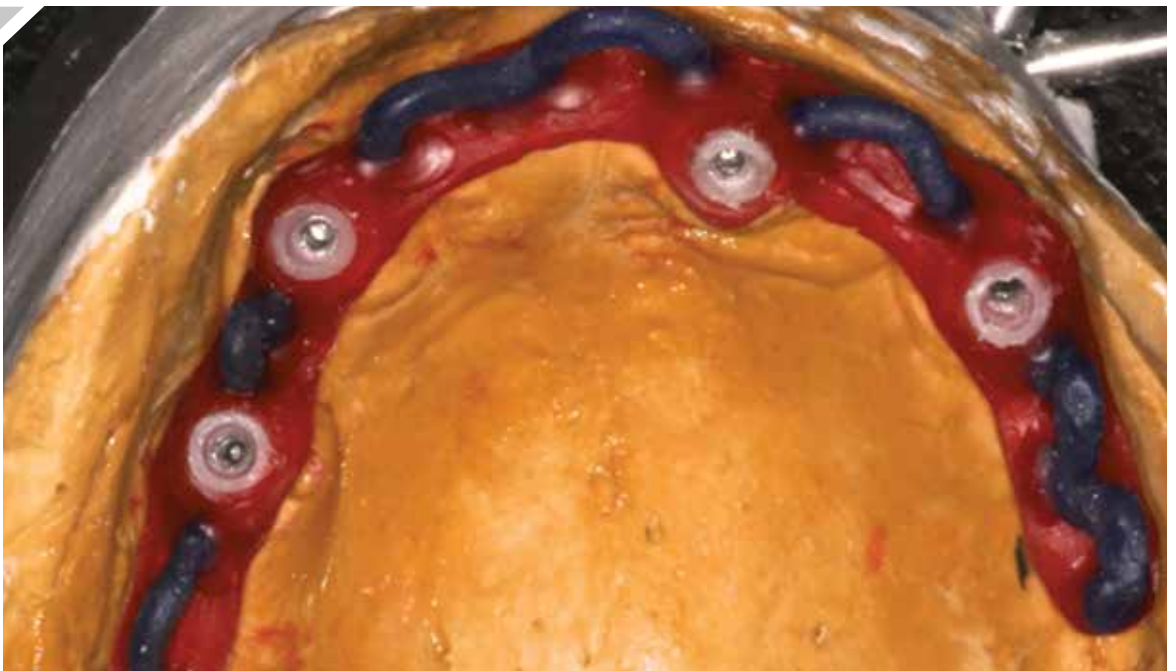Final
Impression
Closed Bite



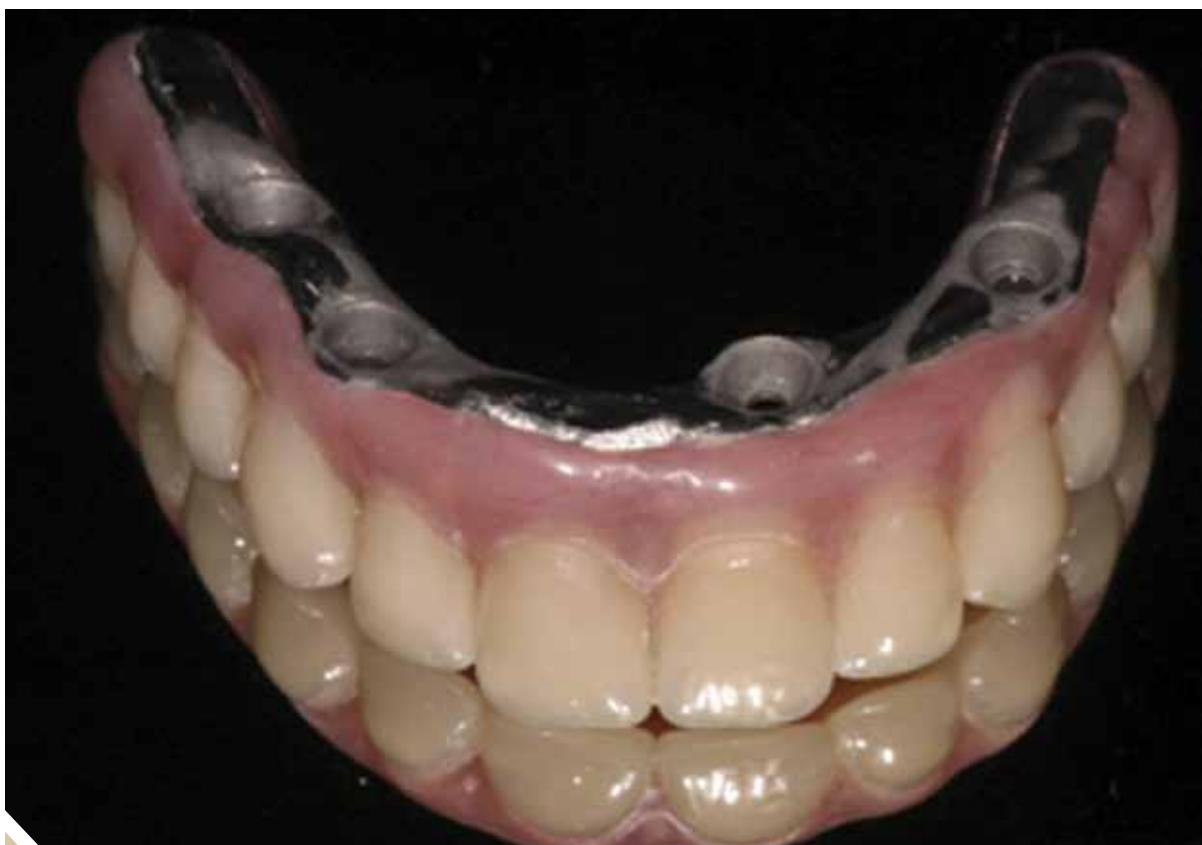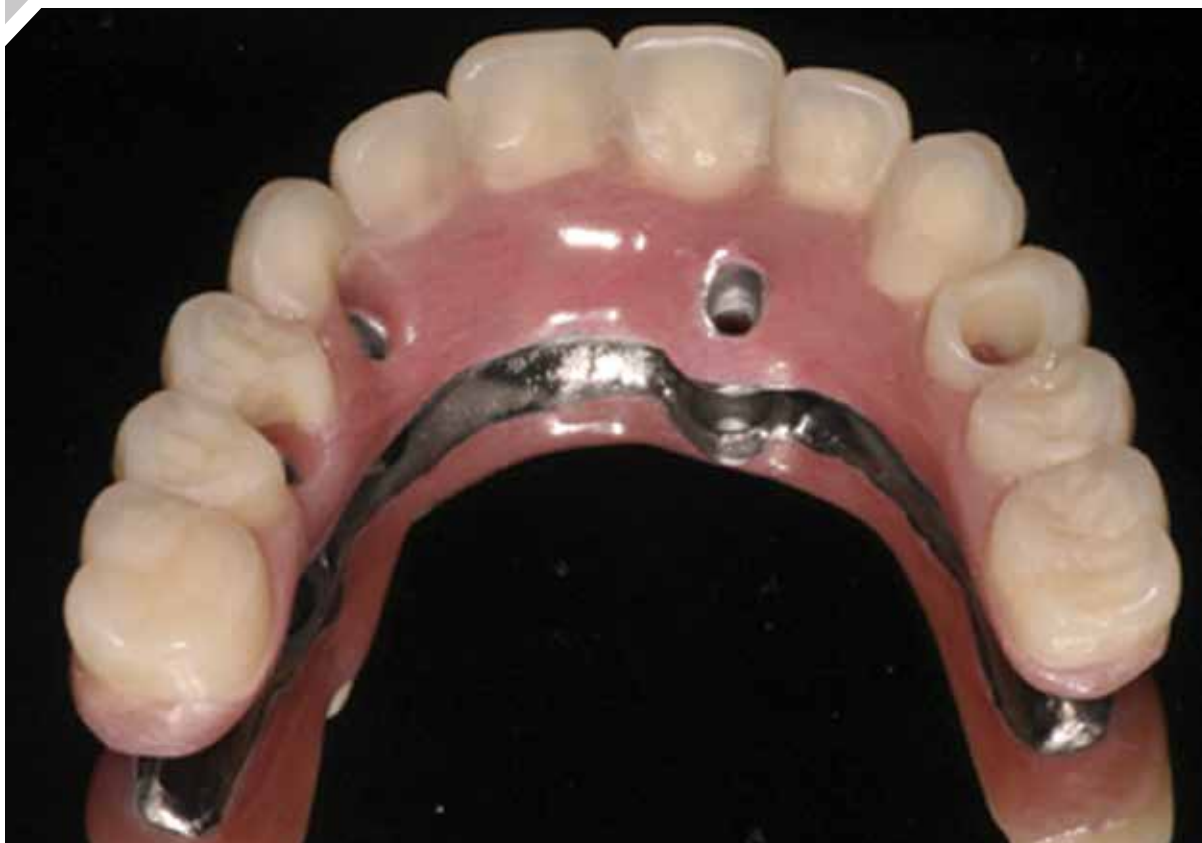Placement
of
Abutment
Replicas



Wax Lab
Bar

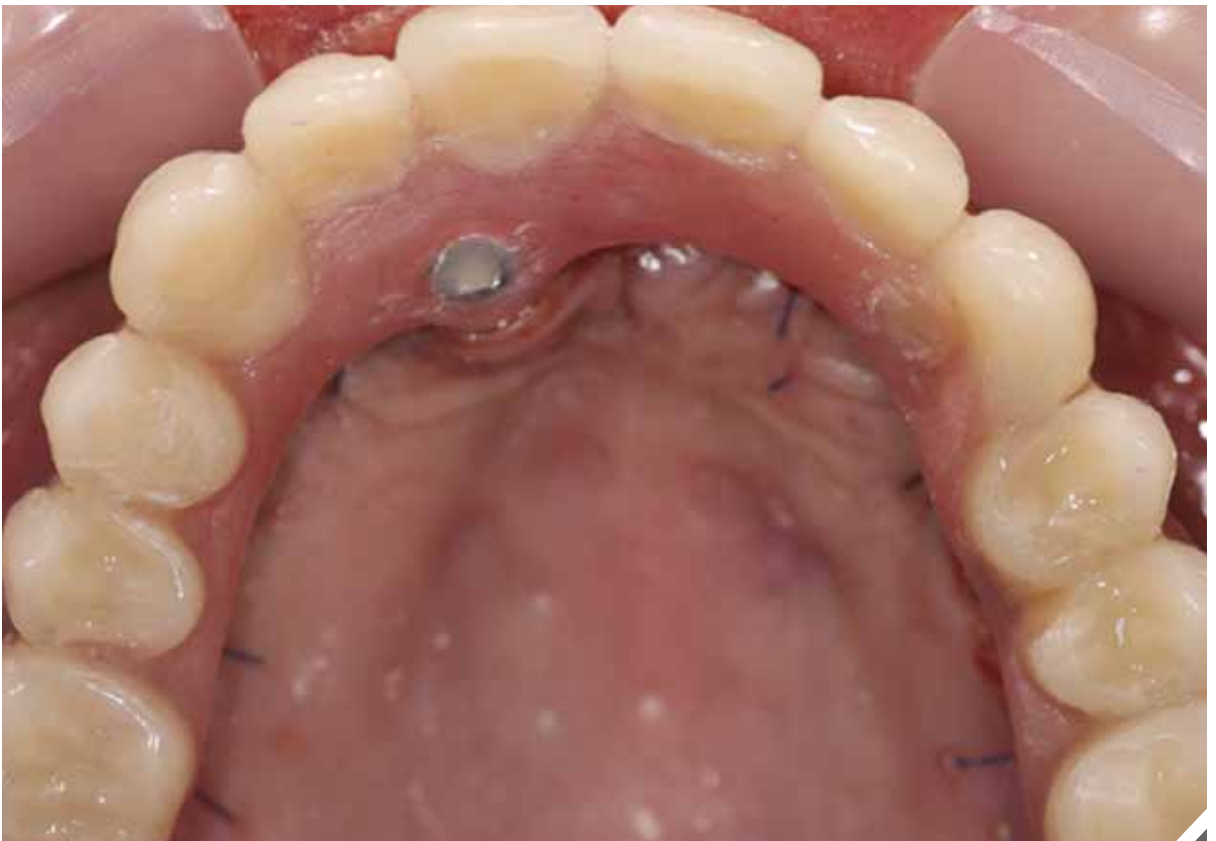
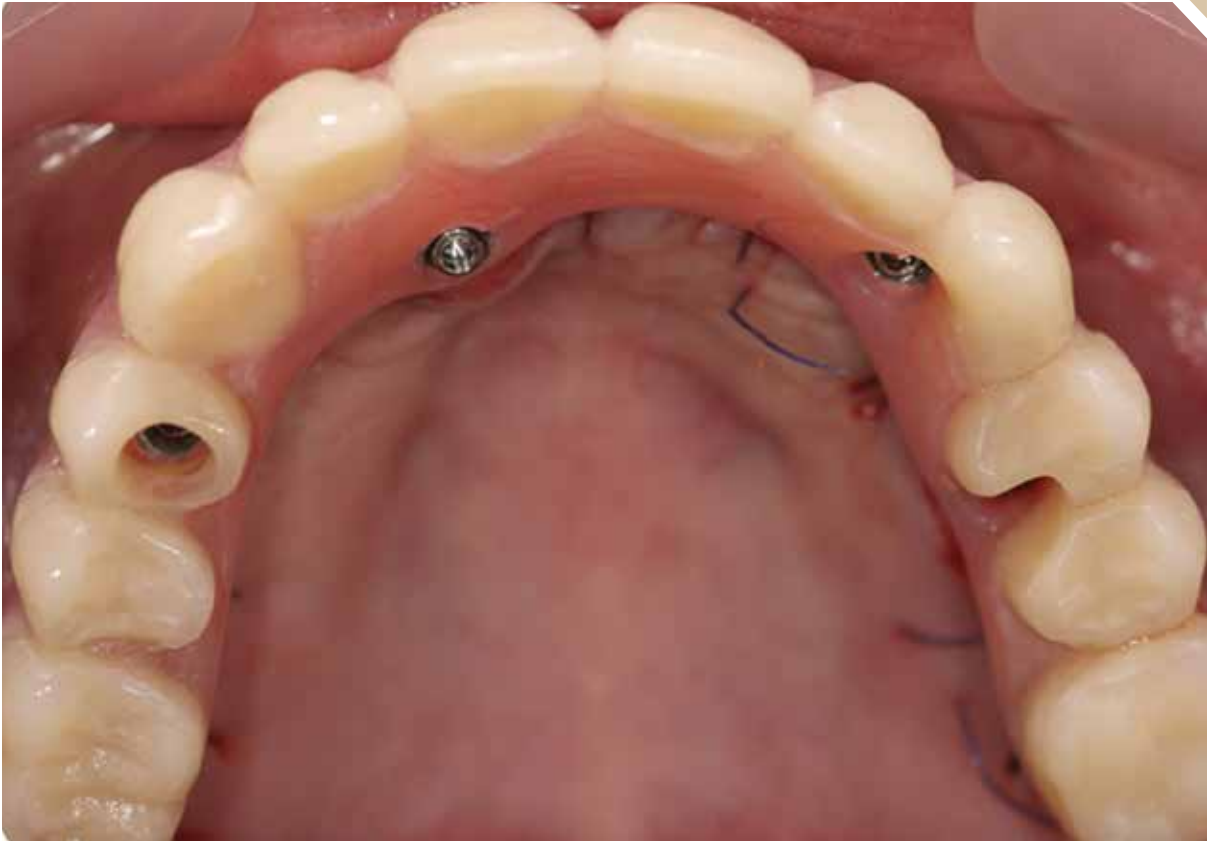
Final Denture
With Co-Cr Bar Type

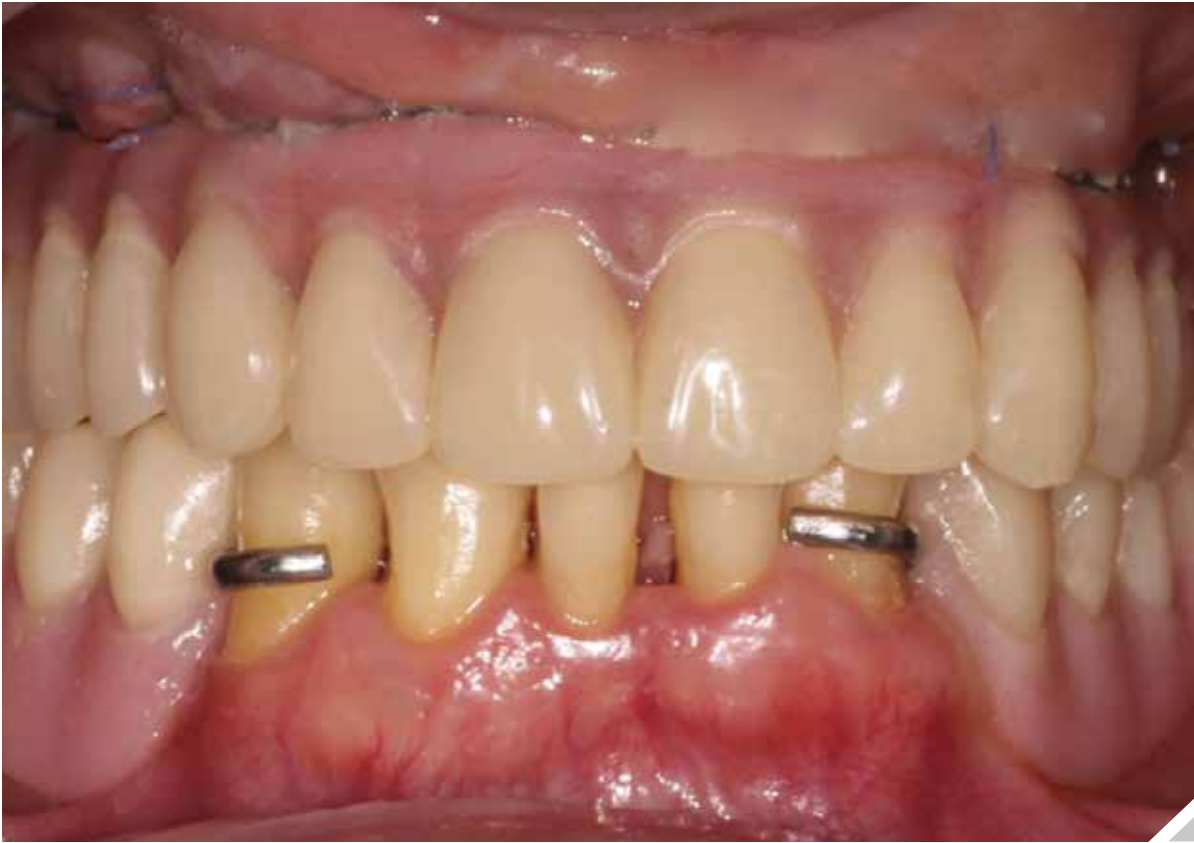

Final Denture
With Co-Cr Bar Type

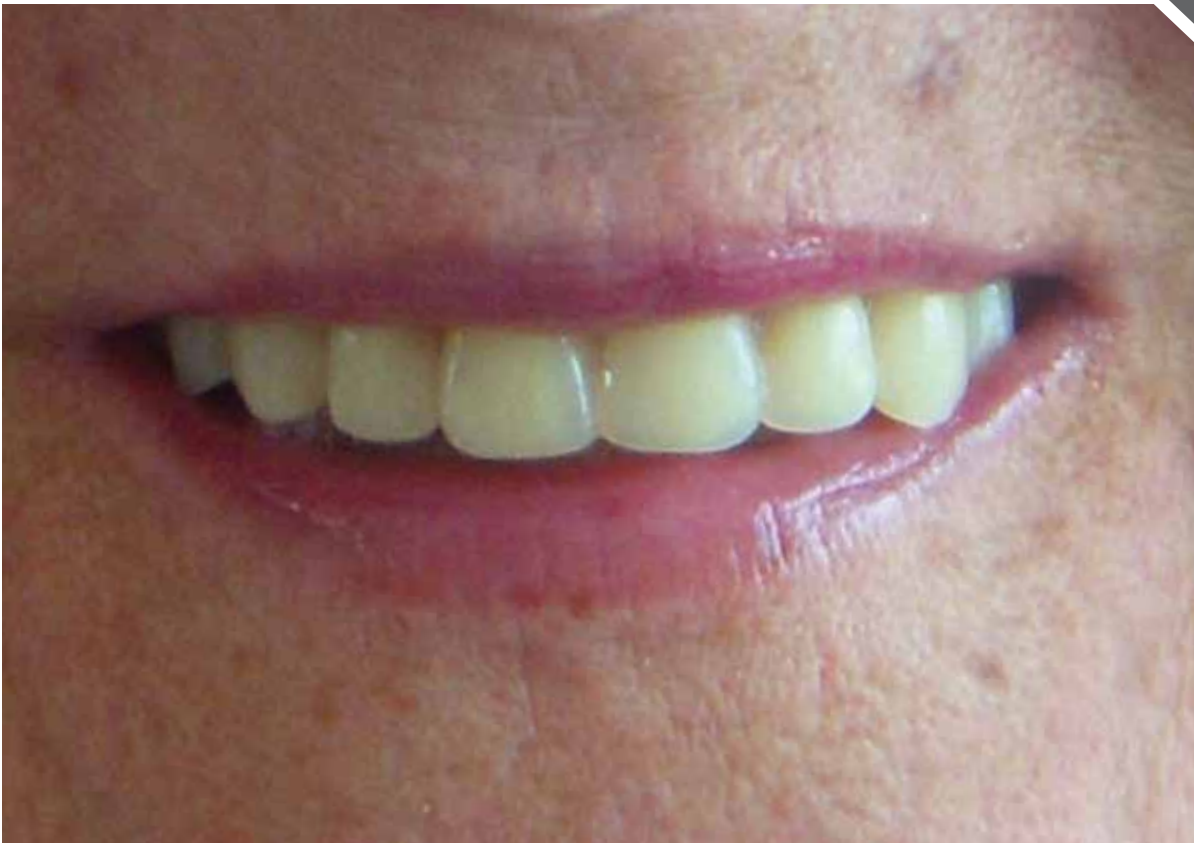Prostheses Placement
24 Hours After
Implants Surgery



Resin in
The Holes



Final
Prostheses



Final
Restoration

LEAVE
LIMITS
BEHIND

Fully Edentulous Rehabilitation Using the All-on-Six/Four Concept with TMA™- Multi Unit | Dr. Shyam Mahajan, India

A 60 year old male patient fitted with a complete denture wear for the last 5 years and desired a fixed prostheses.

X-ray shows bone deficiency beneath maxillary sinus and in posterior mandible. Treatment plan included an All-on-Six restoration on Adin Touareg™ implants for the maxilla and All-on-Four restoration for the mandible. Patient used his old dentures for 4 months.

A hybrid fixed prosthesis was made.
Patient is very happy and can eat all types of food and looks much younger.

Adin Implants used:

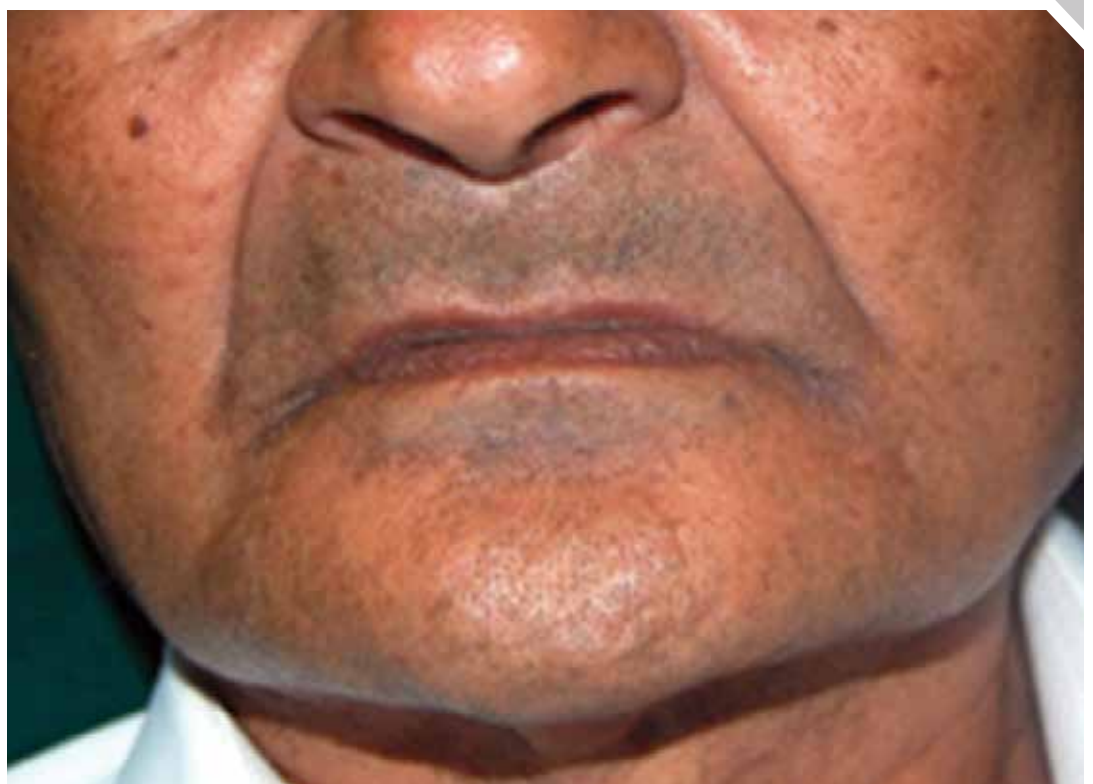
Maxilla-Tilted Implants Posterior: Adin Touareg™ 3.75mmDx16mmL with straight and Angled TMA™ abutments.

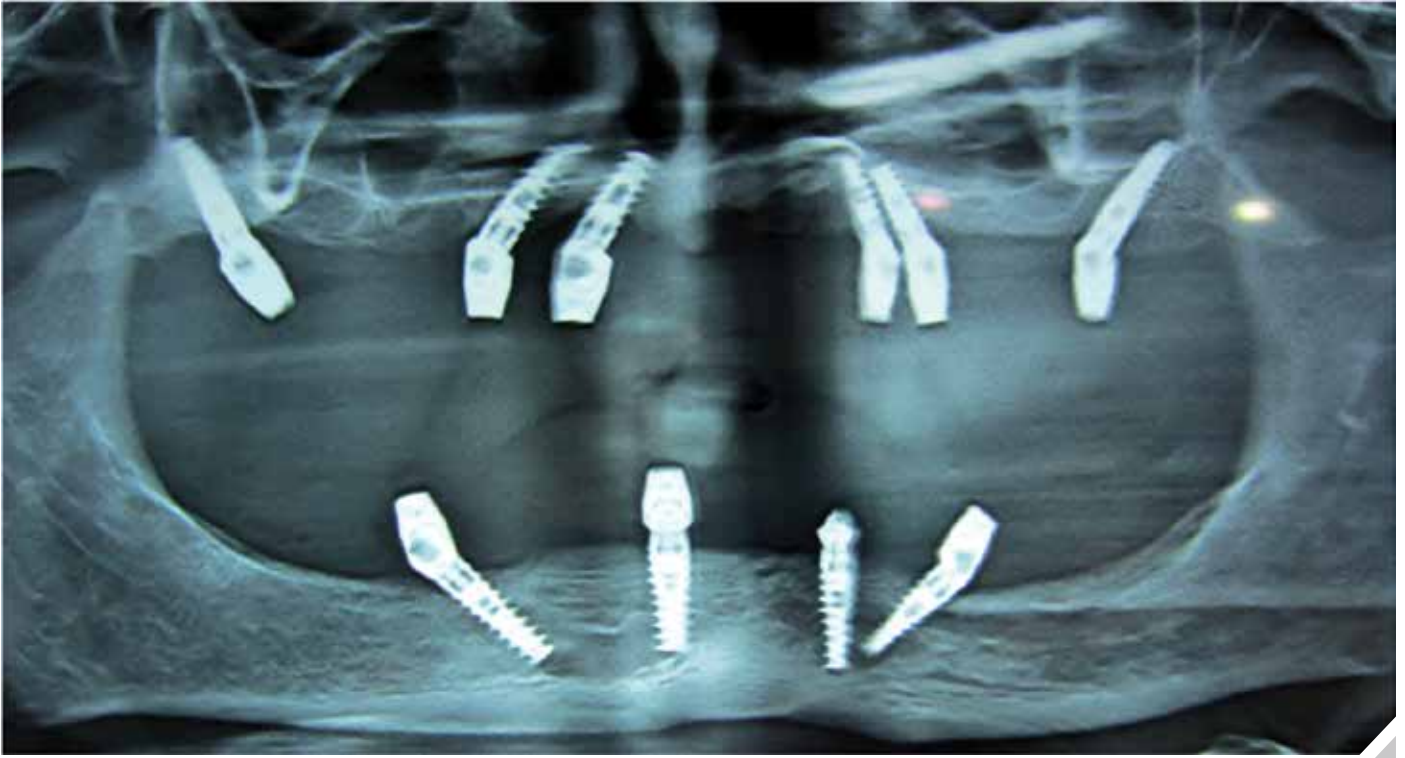
Tilted Implants Anterior: Adin Touareg™ 3.75mmD x 13/11.5 mmL with 30° TMA™- Multi Units.

Mandible with 17° and straight TMA™ Multi Units:
Adin Touareg™ 3.75mmDx13mmL and
3.5/4.2mmD x 10 mmL.

Case 2

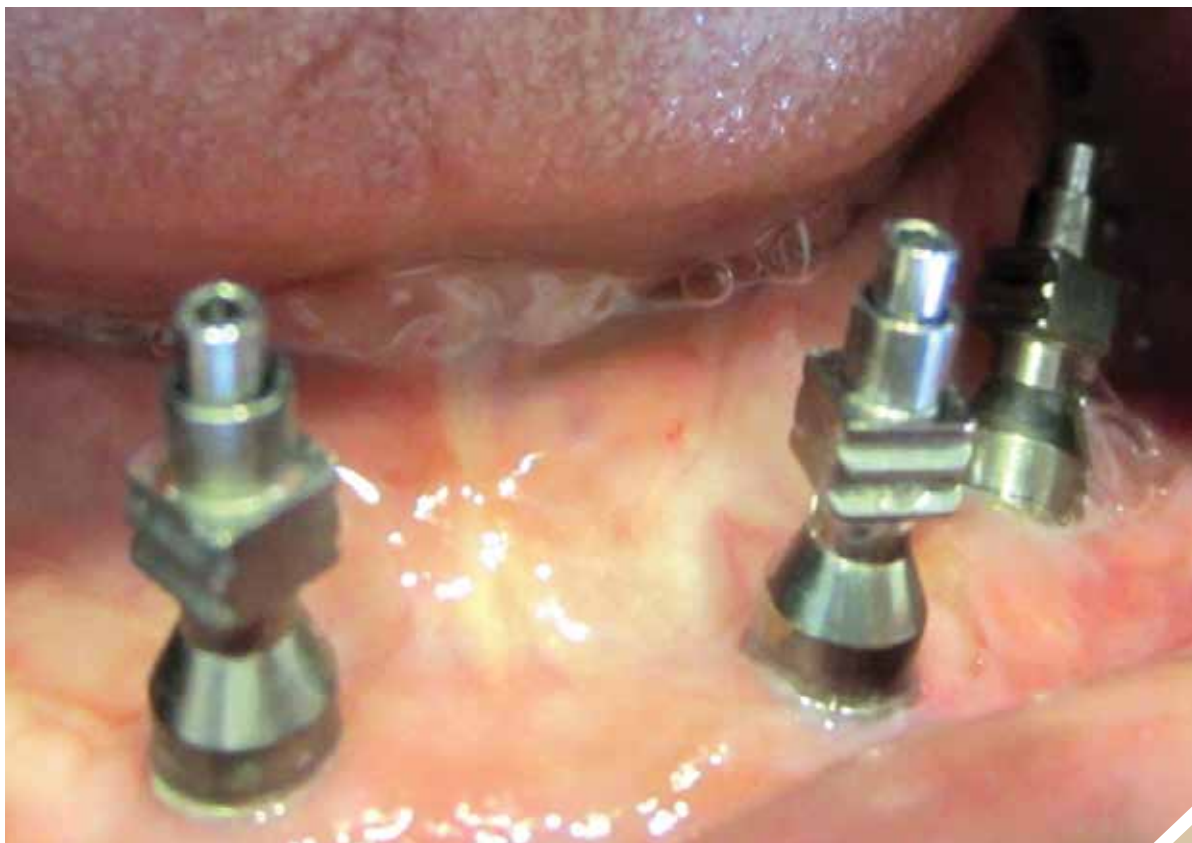Patient is wearing dentures.
Due to loss of vertical height & lack of retention, he looks older and has difficulty chewing



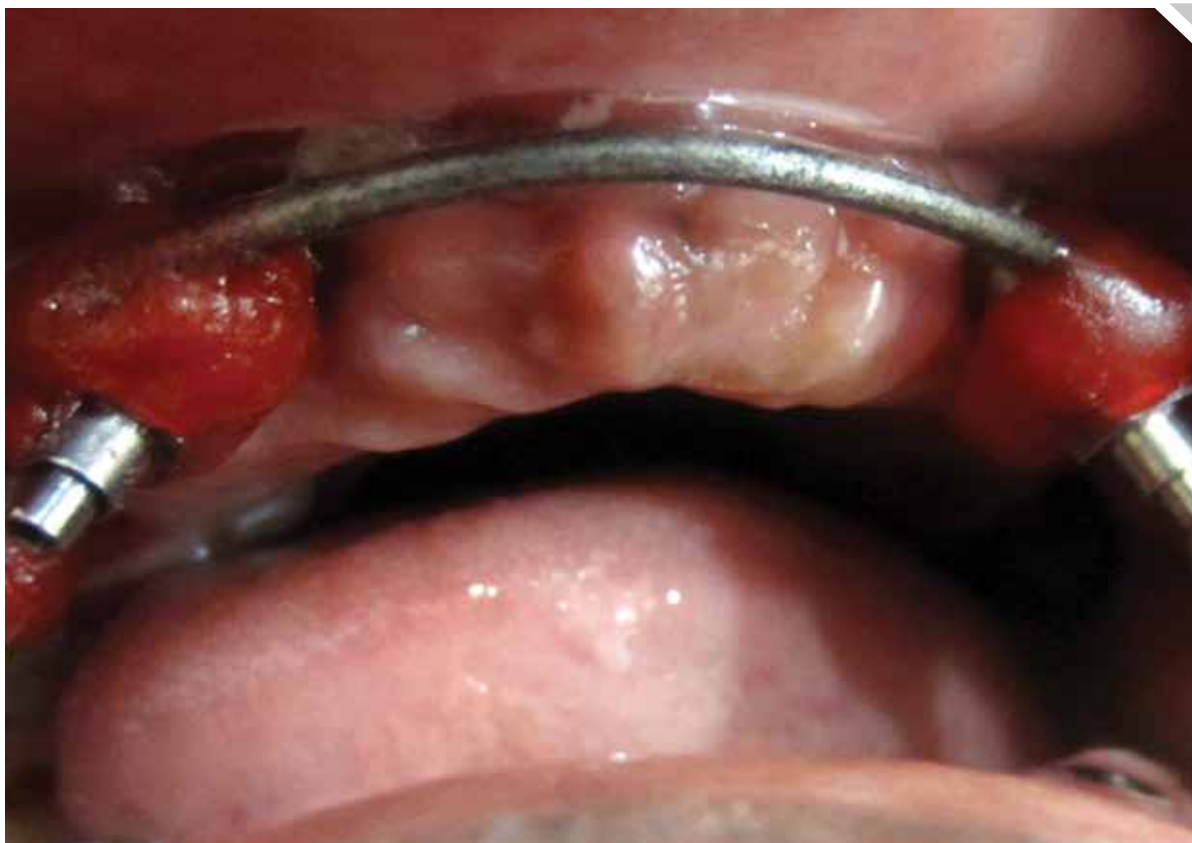

Maxillary angled implants- distal to sinus pterigopalatine & mesial. Other longer angulated implants to achieve bicortical support.
For Mandible mesial to mandibular foramen

LEAVE LIMITS
BEHIND

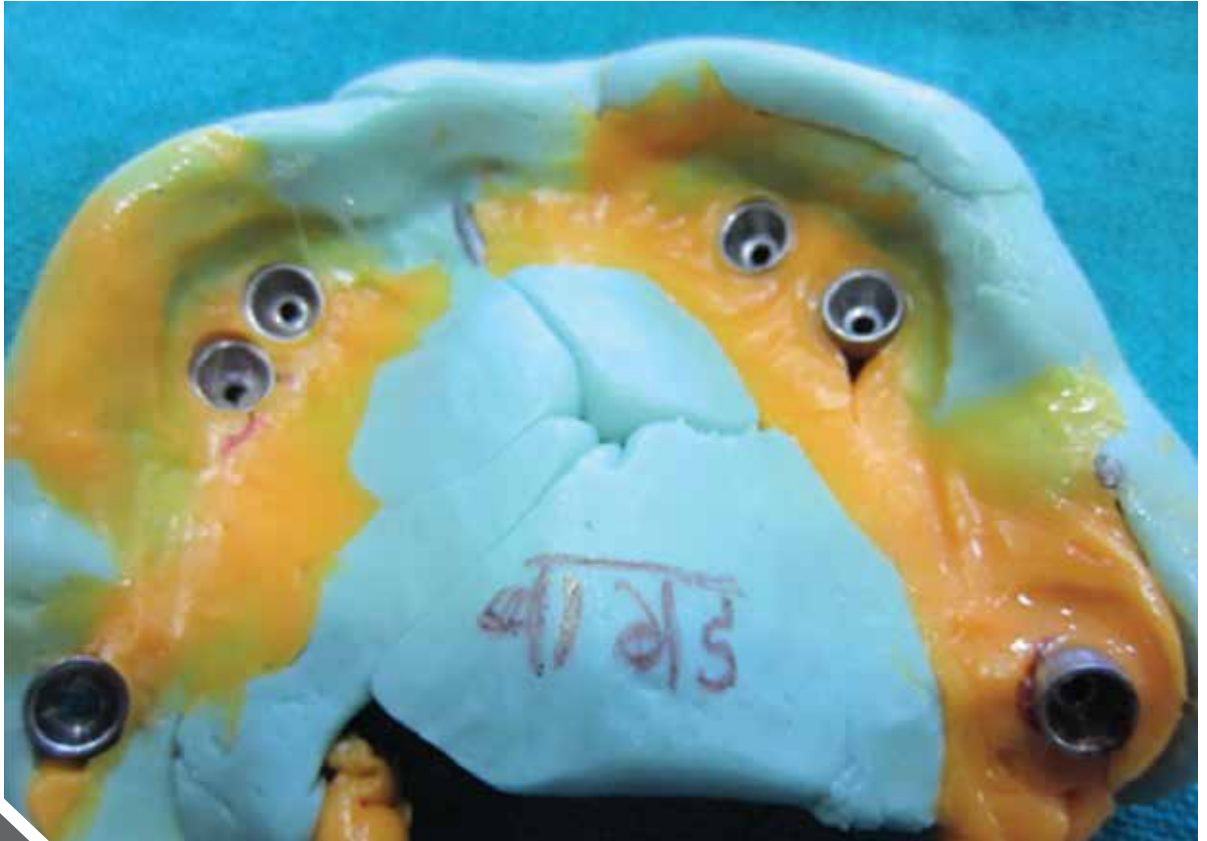

TMA™
Impression
Coping
Open Tray

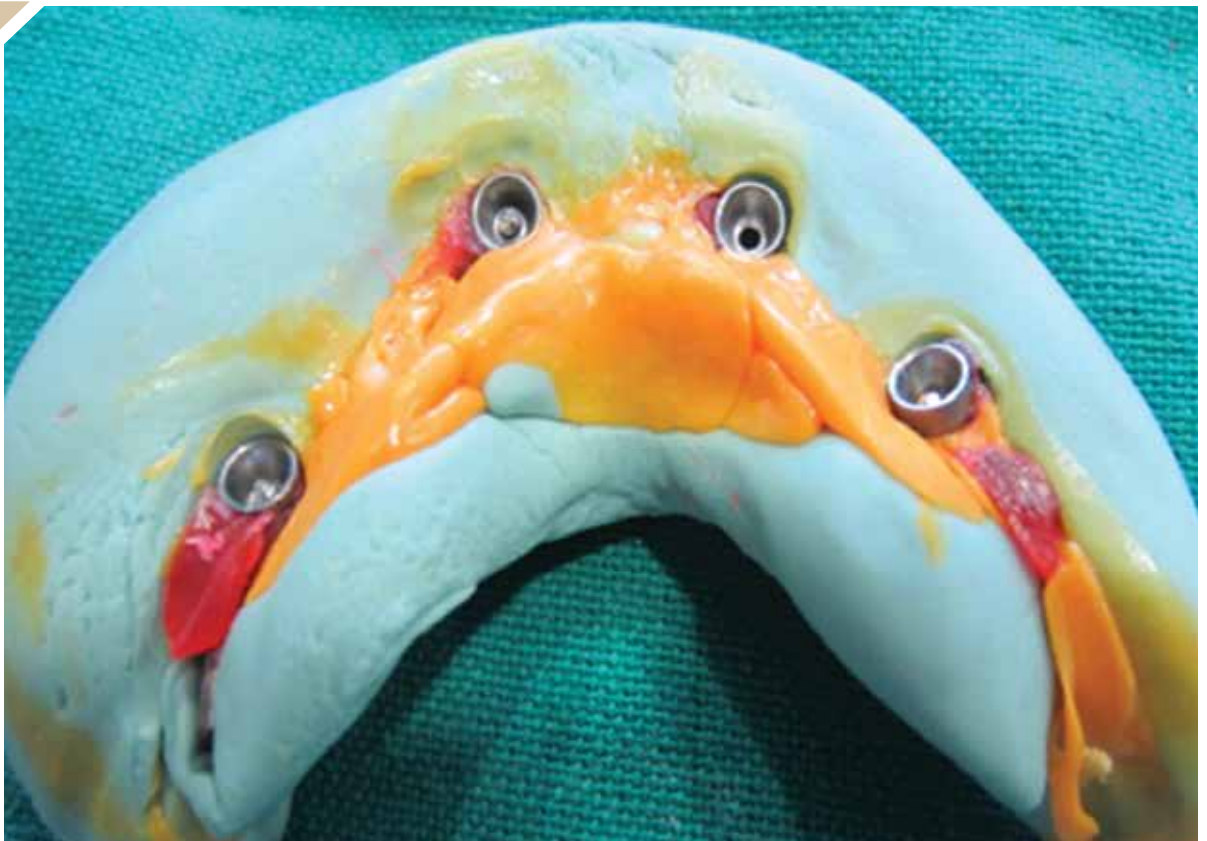

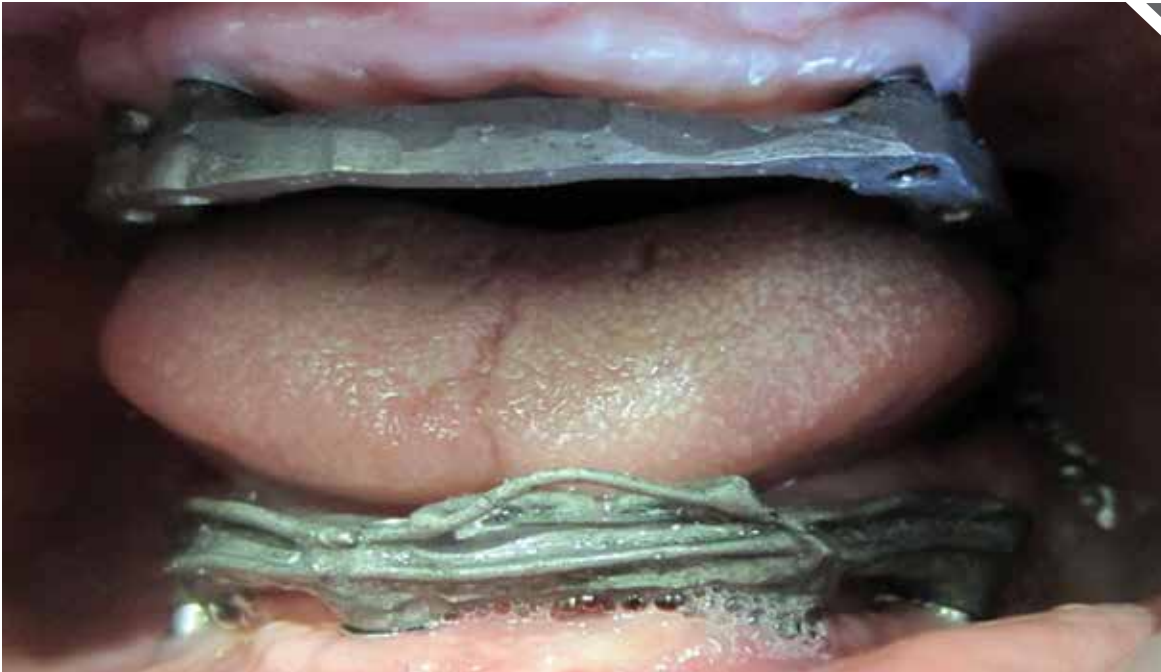Impression
Skeleton
without
Tray

Impressions



Impressions

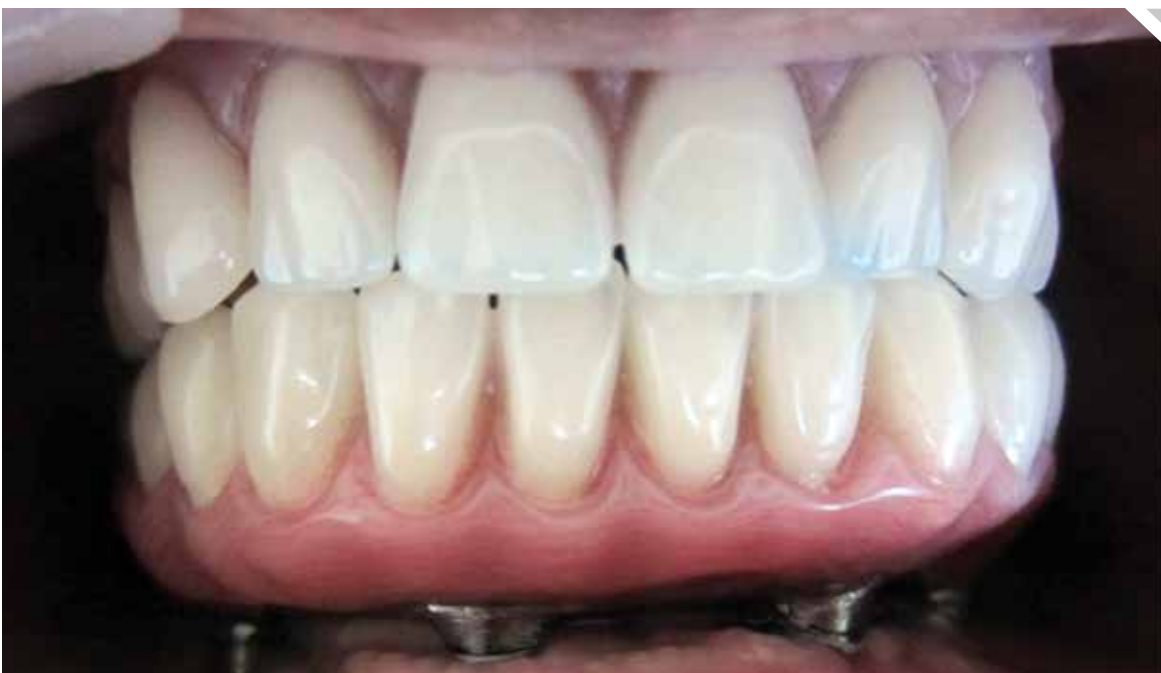



Framework
Trial

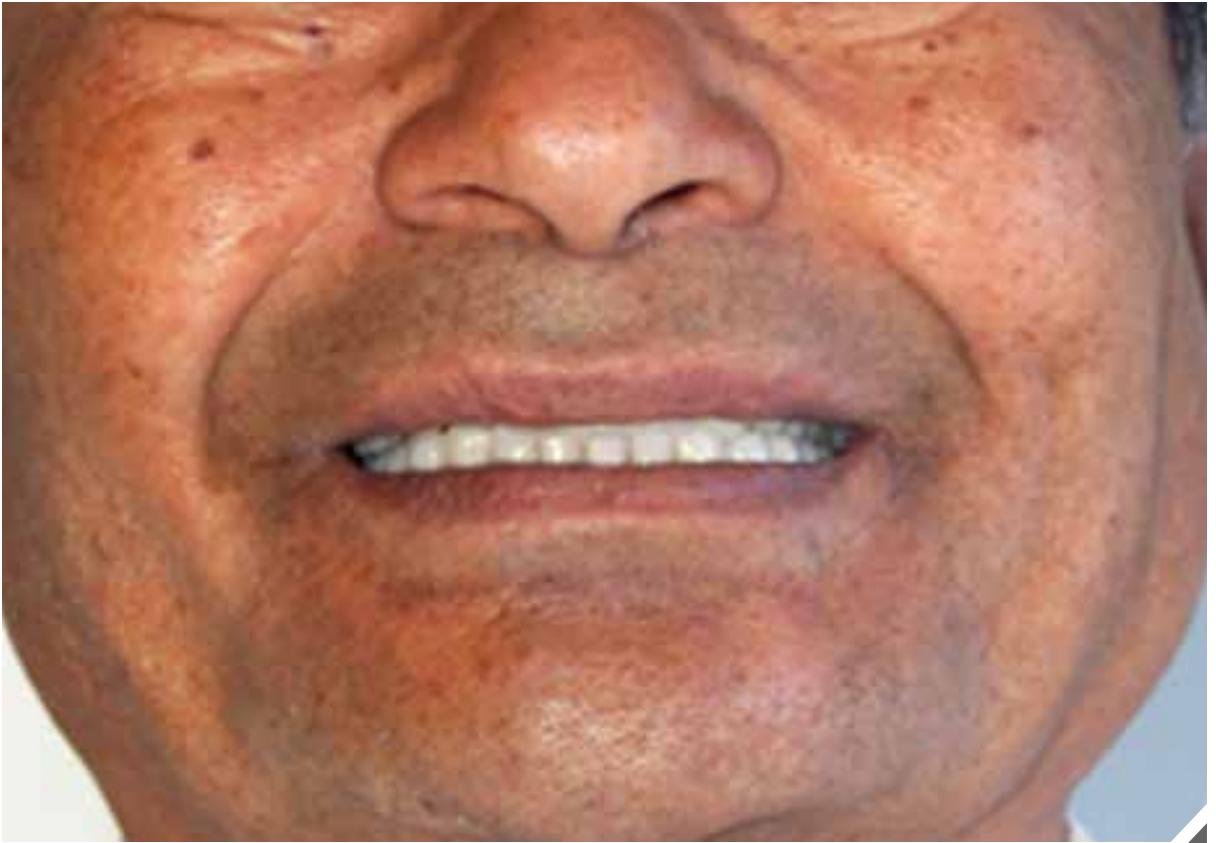
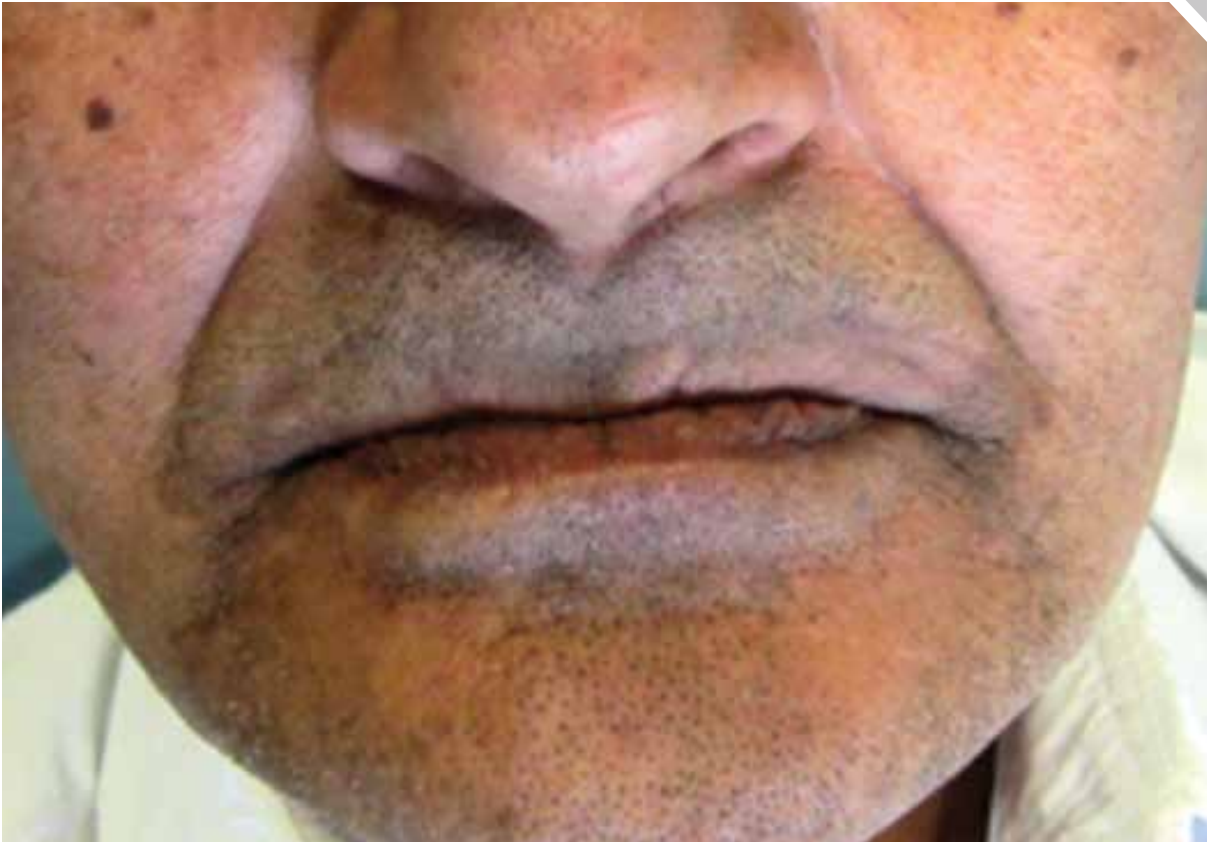
Jaw
Relation/
Pre-Casting
Trial



Fixed
Hybrid
Prosthesis

Pre Op



Post Op



Adin Dental Implant Systems LTD
Industrial Zone Alon Tavor
POB 1128, Afula 1811101, Israel
Tel: +972-4-6426-732
Fax: +972-4-6426-733