

The Use of
NARROW PLATFORM 3.0mm
Implants

Ziv Mazor D.M.D

Touareg CloseFit™ NP
Case Study

VOL. 1 | March 2013



Case 1

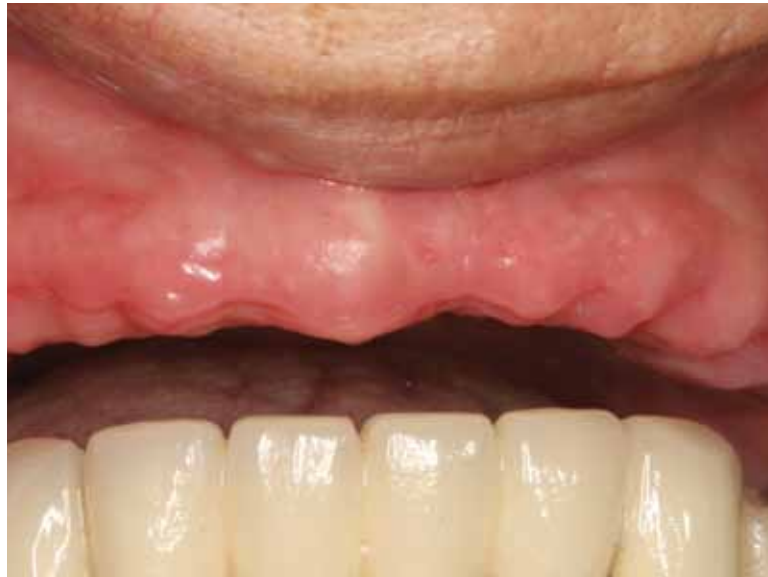A 55 year old patient requiring full maxillary rehabilitation. CBCT revealed ridge deficiency with a crestal width of 3-4.5mm. Treatment plan consisted of anterior Ridge expansion using expanders and placement of six Adin Touareg CloseFit™ NP 3.0mm narrow diameter implants combined with posterior bi-lateral sinus augmentation with simultaneous implant placement.

Immediate loading was carried out on the anterior implants providing the patient with a fixed temporary bridge.

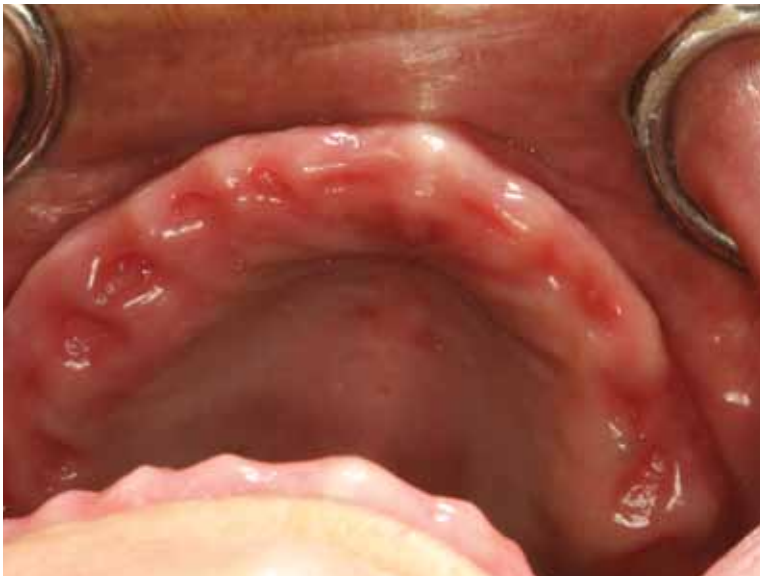6 months post operation impressions were taken for a fixed PFM restoration.

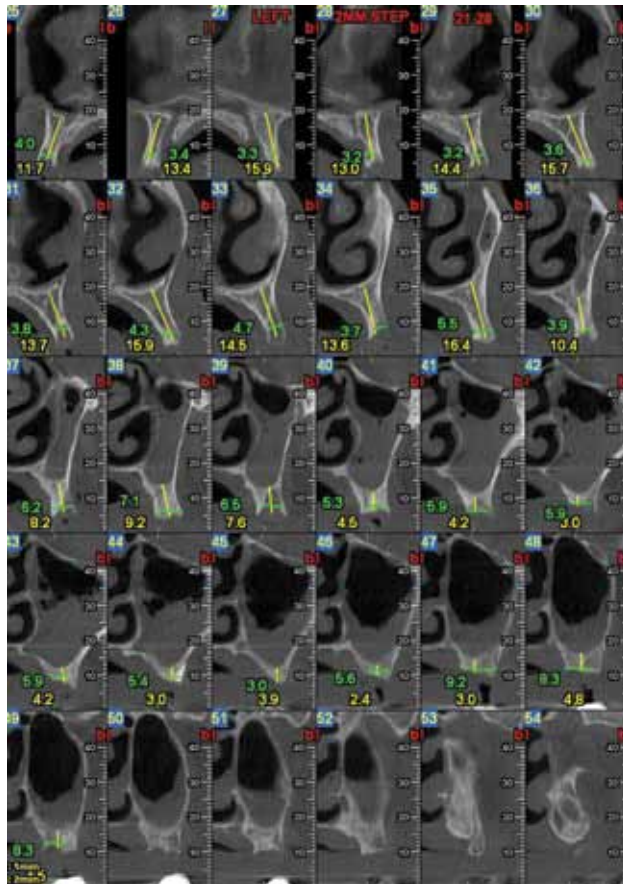
Patient was satisfied and a 2 year follow up revealed implant stability and bone conservation around the implants.

Clinical view

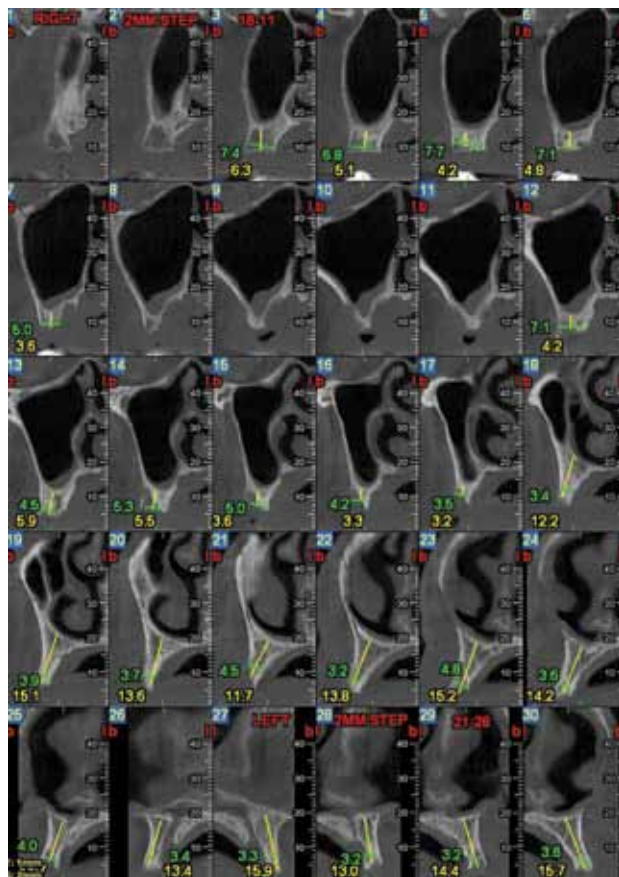


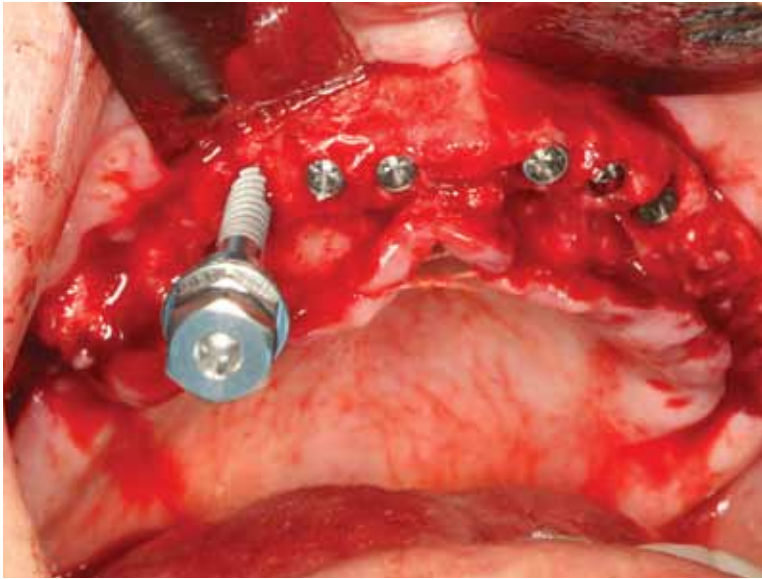
Palatal clinical view



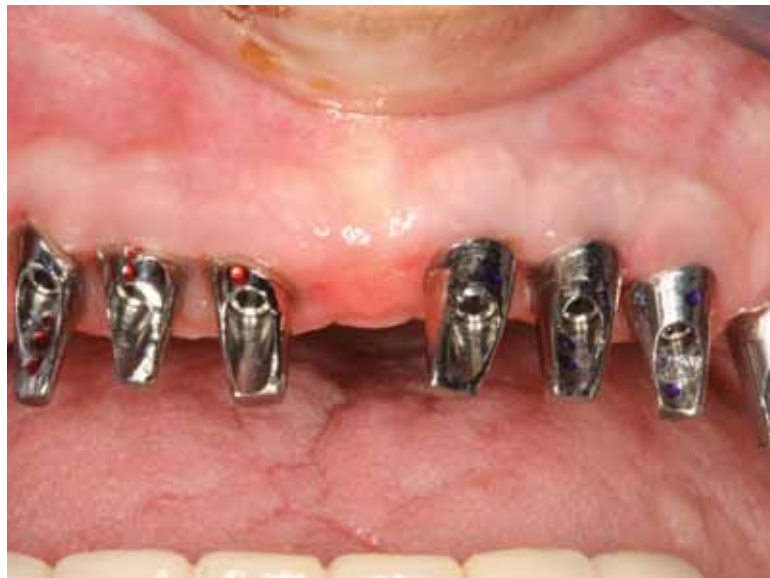

CBCT showing the narrow ridge dimensions



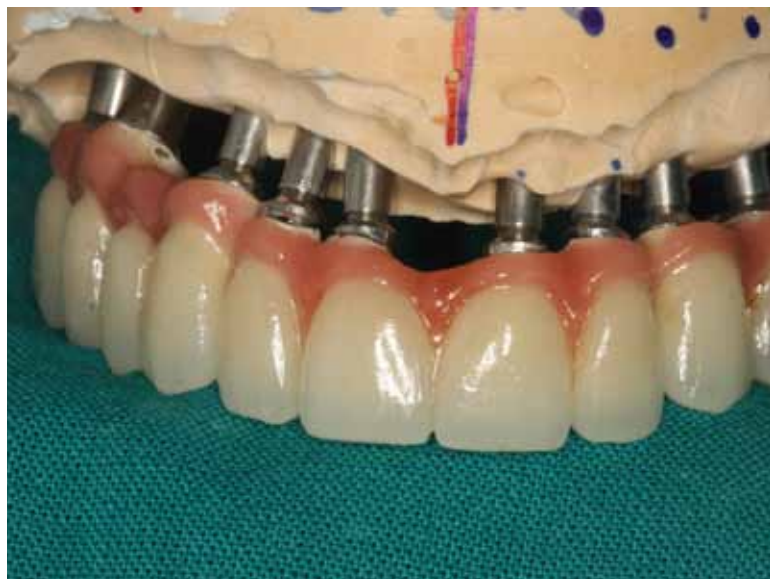

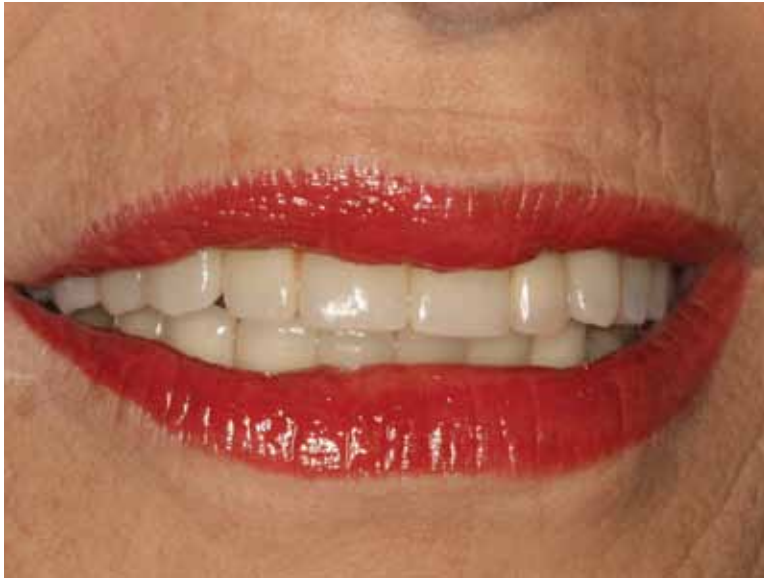NP implant
insertion



Abutment
connection

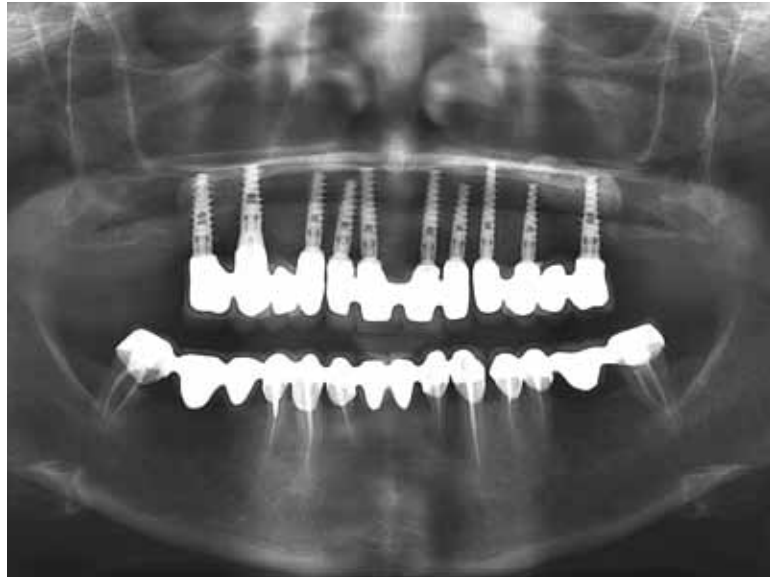
Fixed PFM bridge
on the master model





Clinical
view final
restoration

Panoramic view
1 year post
restoration



LEAVE LIMITS BEHIND

Case

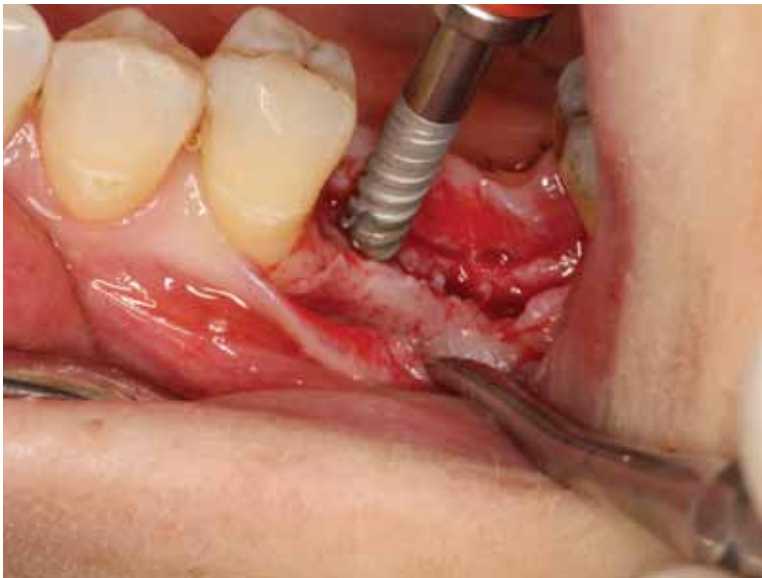
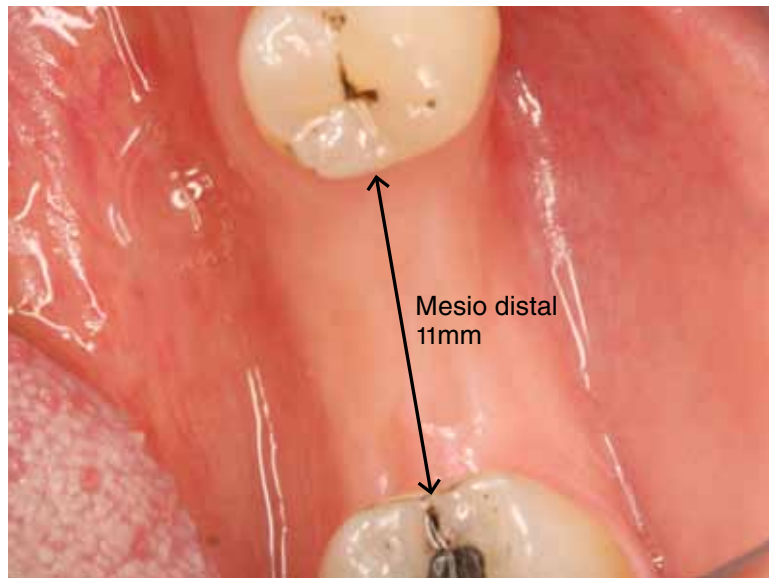
2

A 32 year old patient presented with a missing first molar. Treatment plan consisted in placing two Adin Touareg CloseFit™ NP 3.0mm narrow diameter implants for replacing the molar. Mesio distal space between the teeth was 11mm.

Implants were uncovered after 3 months and a fixed PFM crown was fabricated.

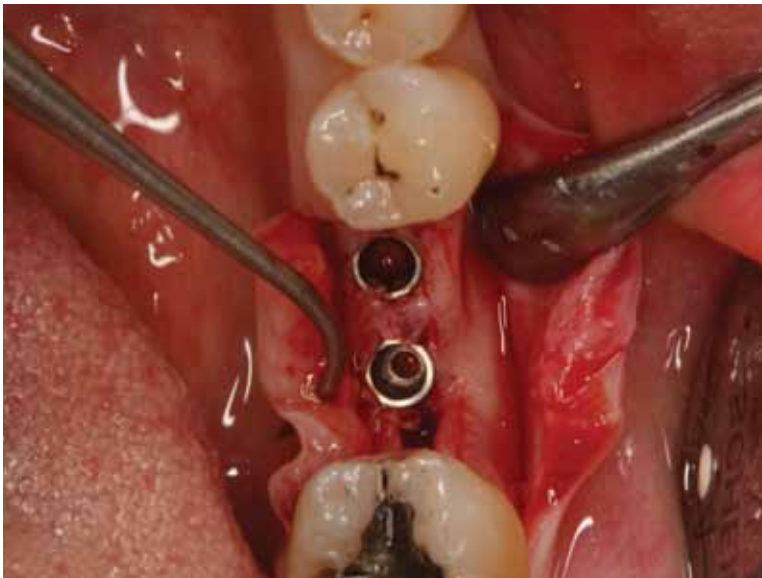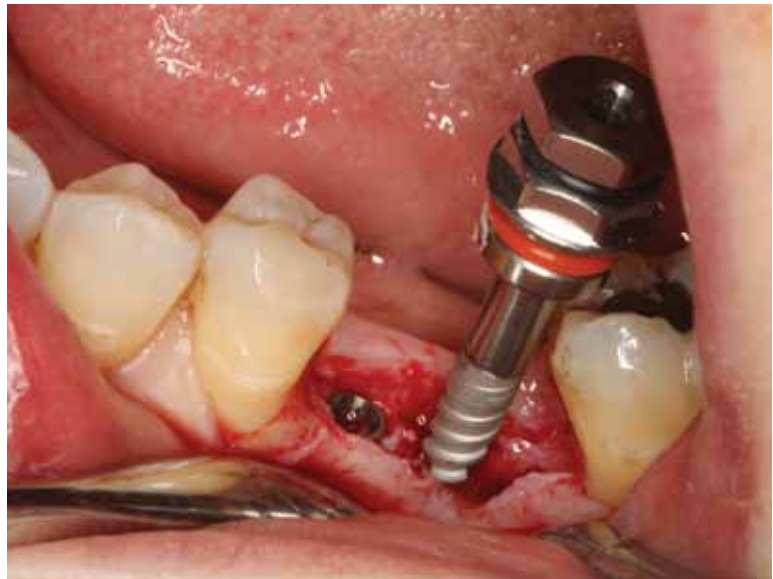Patient was monitored for 3 years with satisfactory result.

Clinical occlusal view demonstrating missing first molar



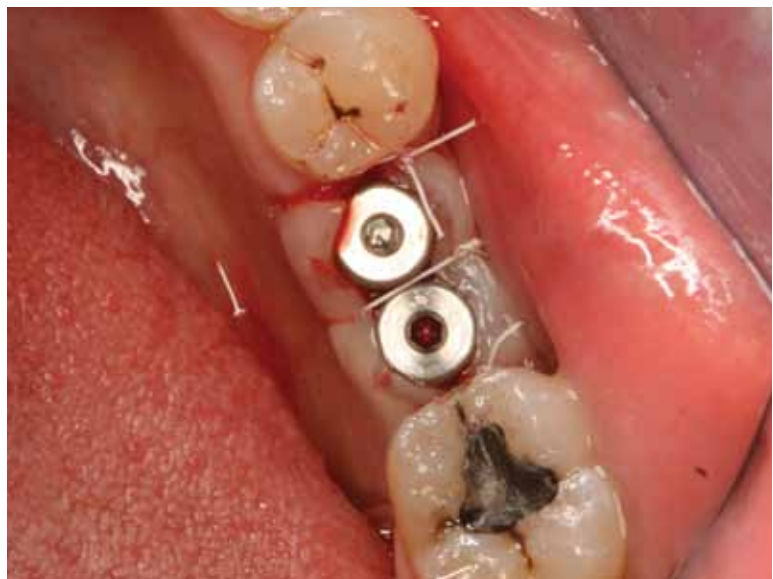NP implants placement

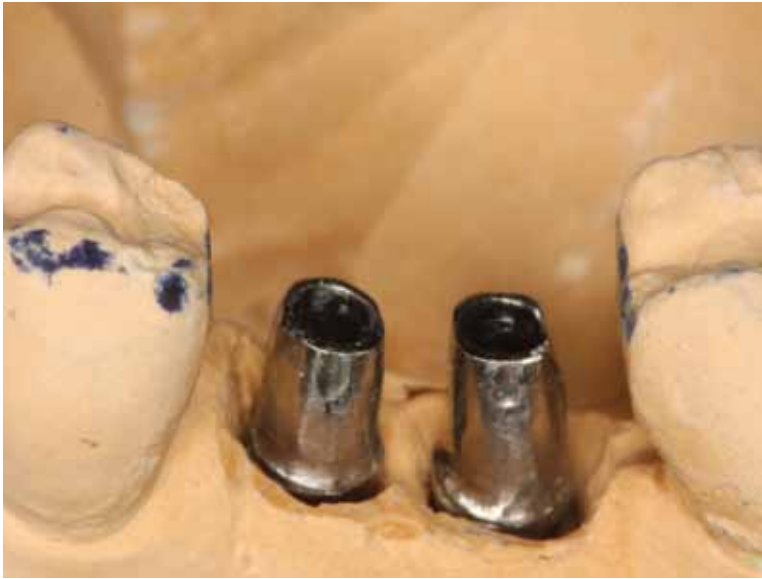NP implants
placement



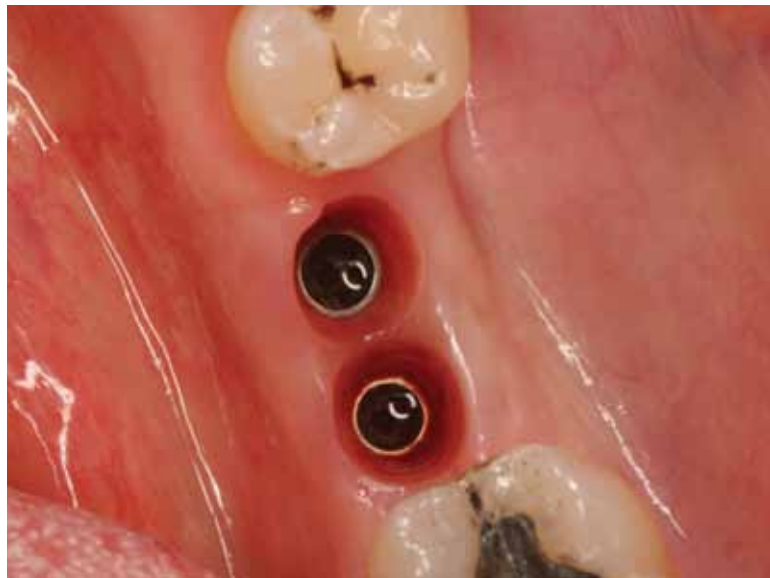NP implants
fully inserted

Implant
uncovering

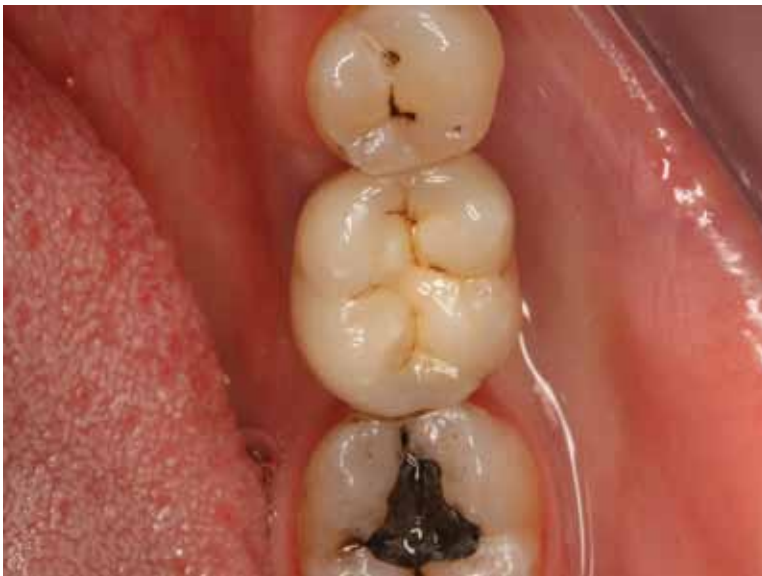



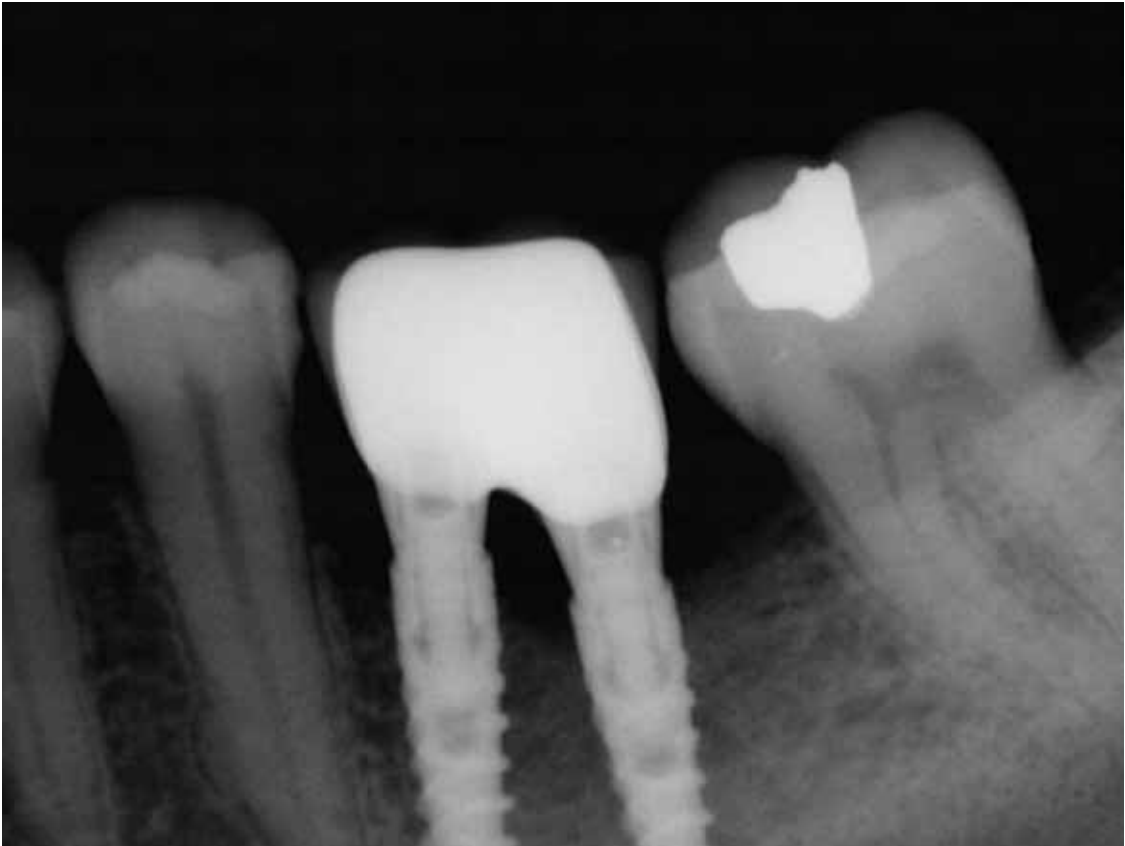Abutment connection
on the master model



Gingival healing
prior to abutment
connection



Clinical view
of final PFM
restoration



Xray taken
1 year post
operation

LEAVE LIMITS BEHIND

Case 3

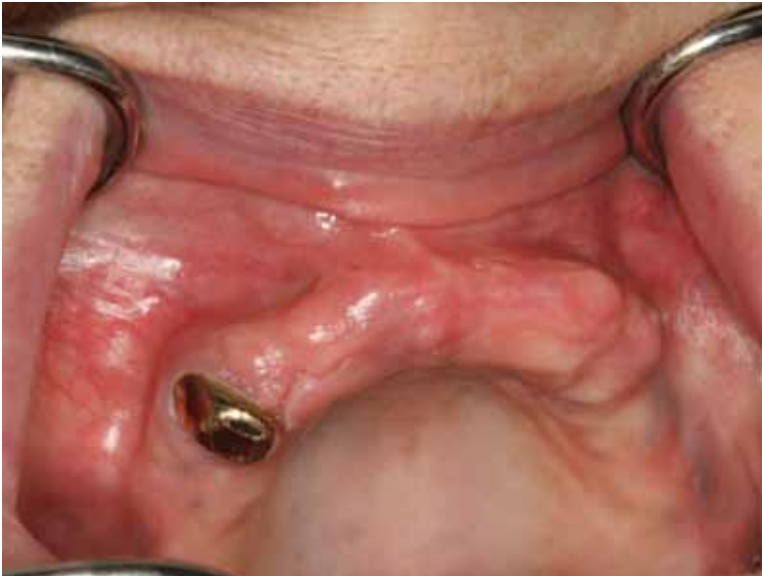A 73 year old female patient wearing a full denture for the past 30 years, presented with a request to get a more stable prosthetic solution. Patient refused to undergo sinus augmentation procedures.

Treatment plan consisted of placing five Adin Touareg CloseFit™ NP 3.0mm narrow diameter implants in the anterior zone combined with sub nasal floor elevation.

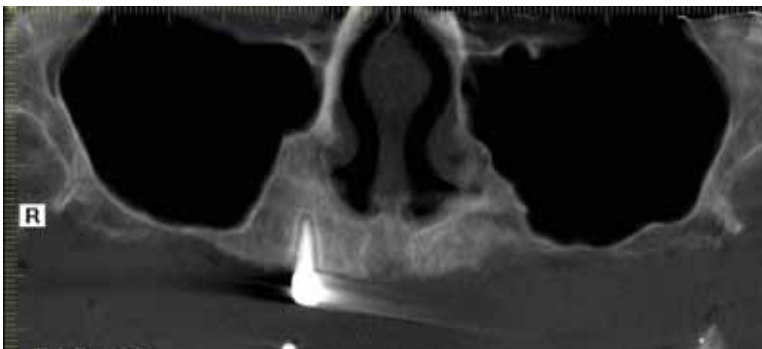
6 months post op implants were uncovered.

Trans Mucosal Abutments were placed and an impression for a CAD CAM titanium based screw retained bridge was taken.

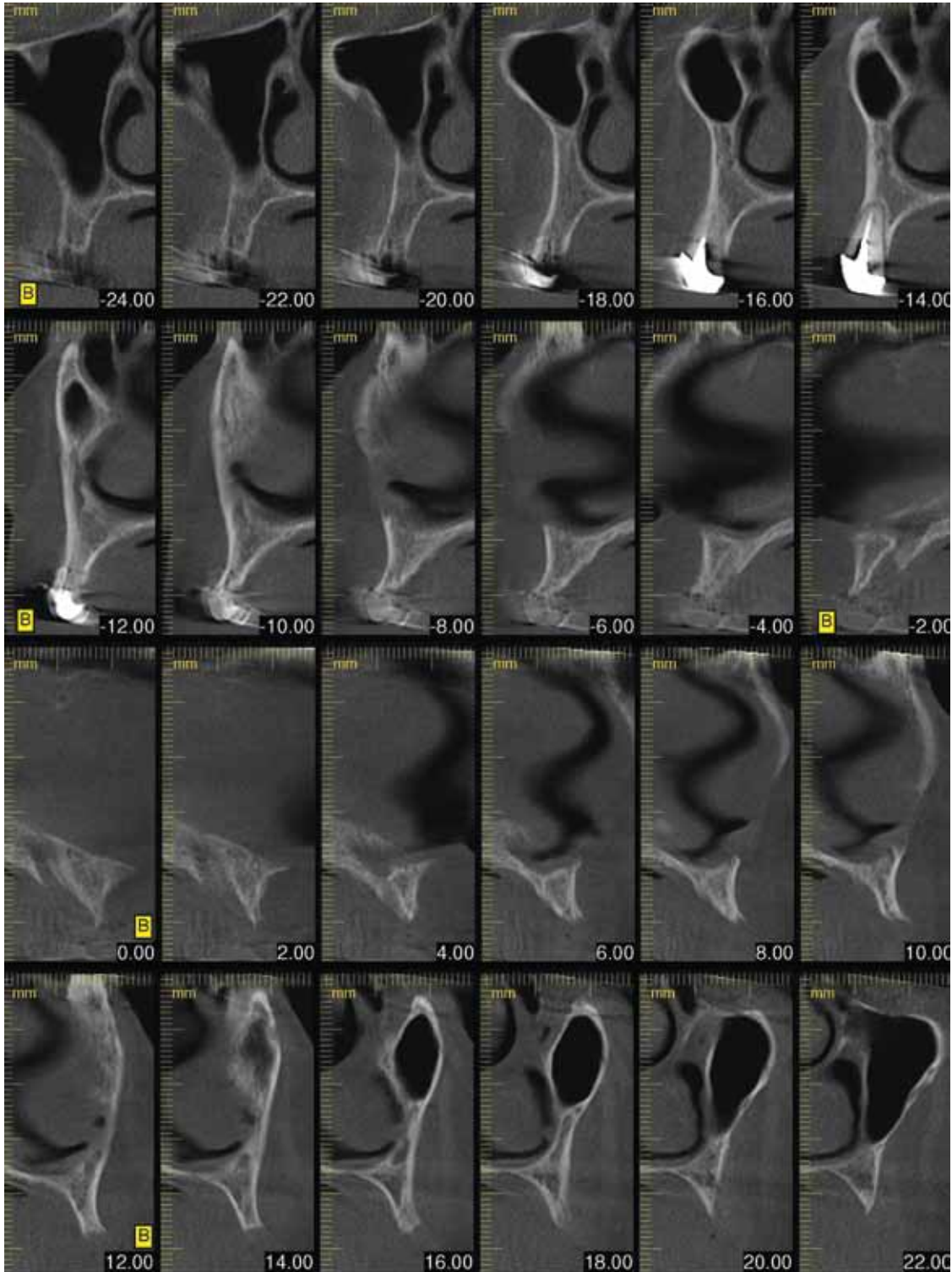
Patient was highly satisfied with the prosthetics and had been followed up for 3 years.



Clinical view

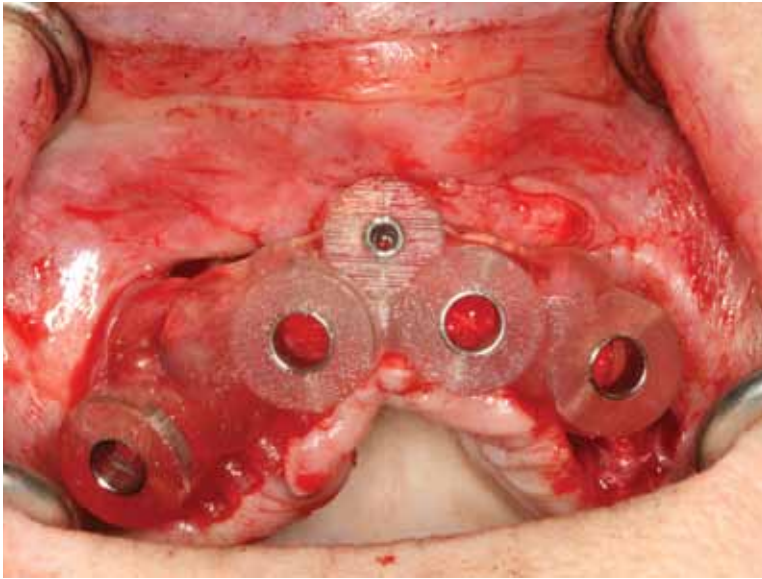


Panoramic and CBCT views of the deficient anterior ridge

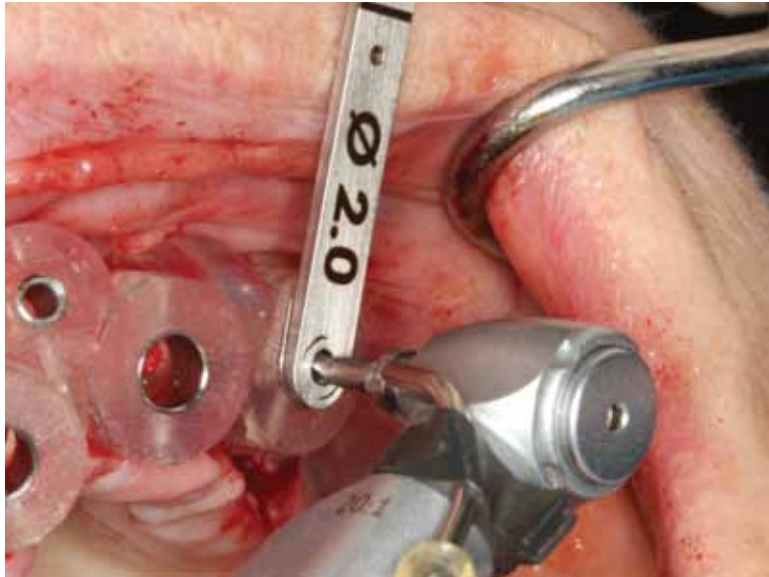

Panoramic and CBCT views of the deficient anterior ridge

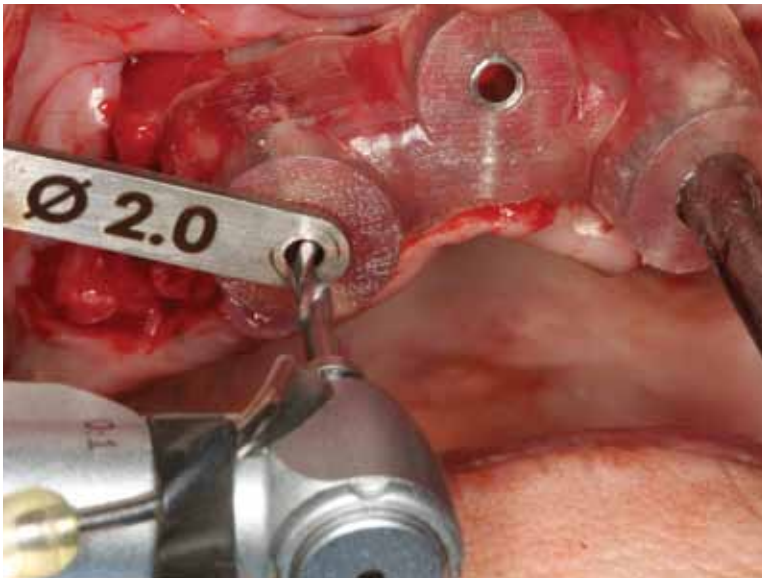Pictures are courtesy of Professor Ziv Mazor



Surgical guide adjusted to the ridge

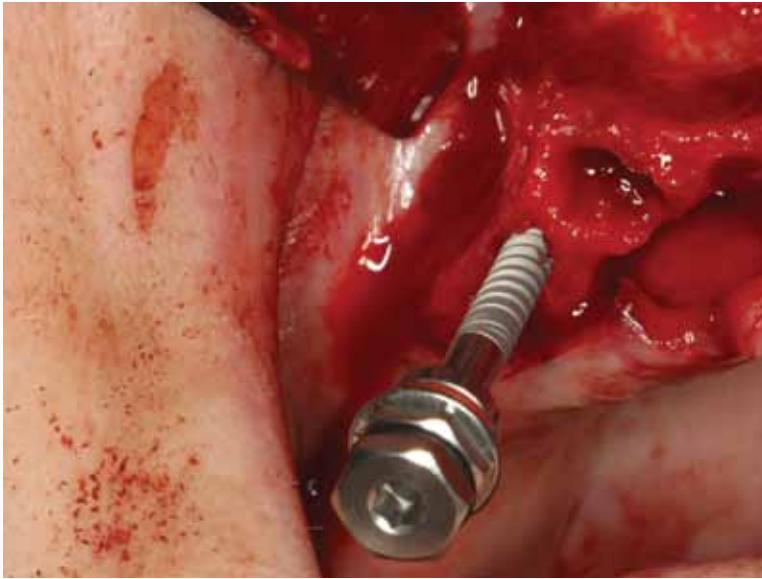


Drilling through the guide

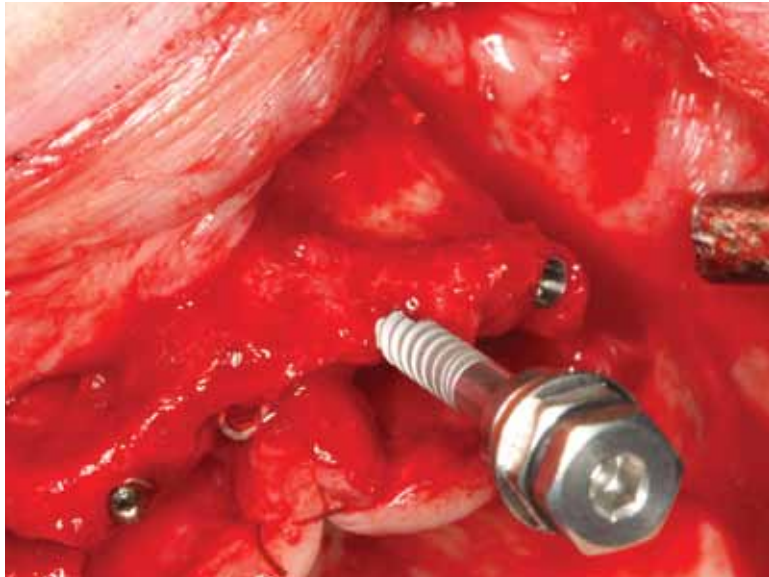


**LEAVE LIMITS
BEHIND**

Pictures are courtesy of Professor Ziv Mazor

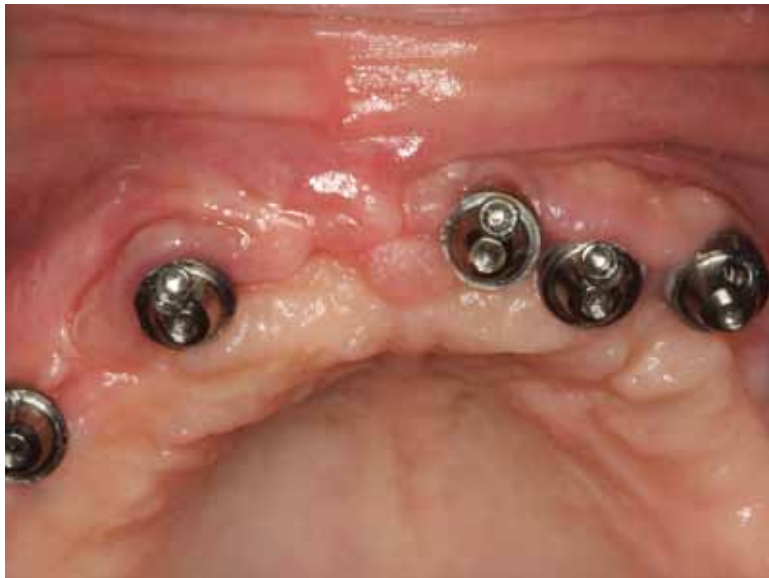

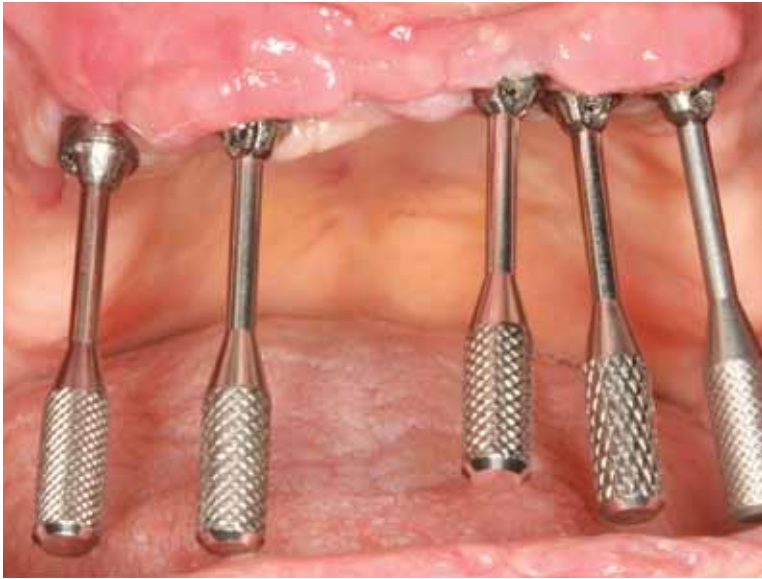
NP implant placement



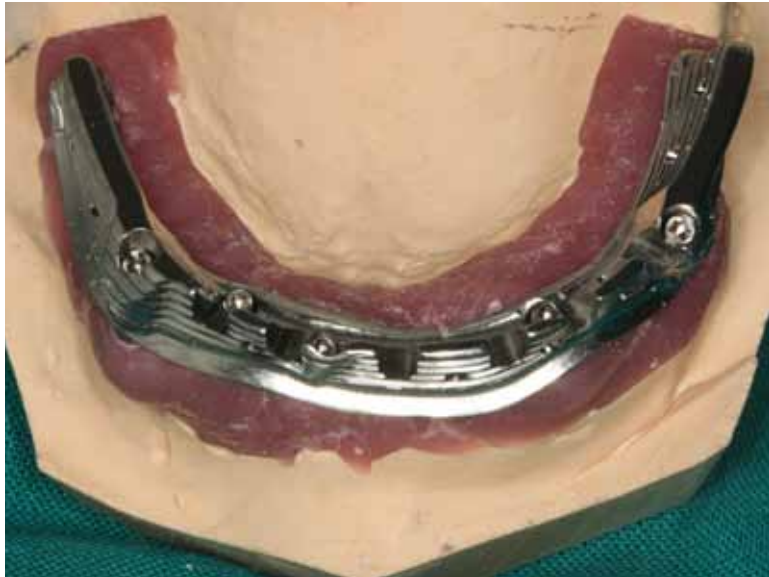NP implant placement

TMA connected to the NP implants

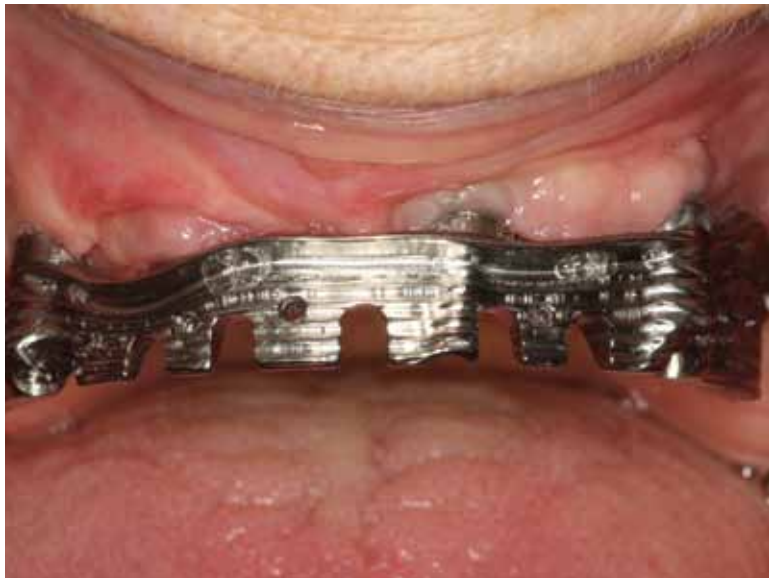



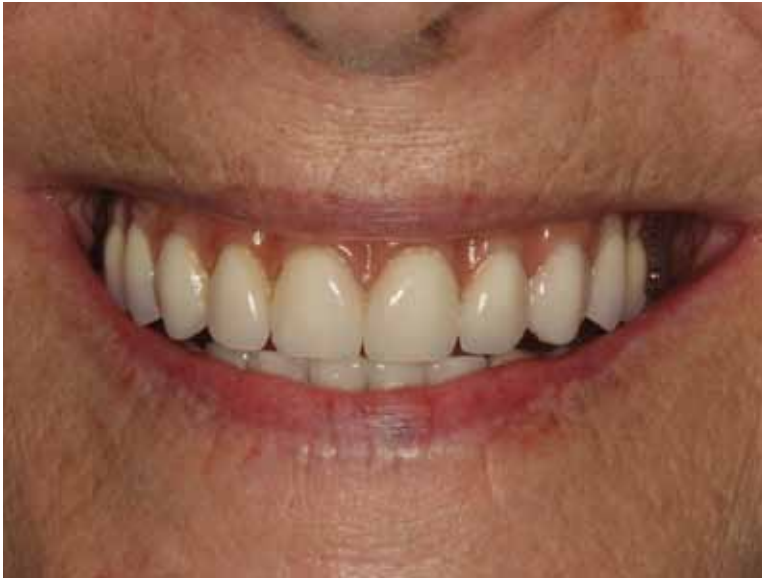TMA connected to the NP implants



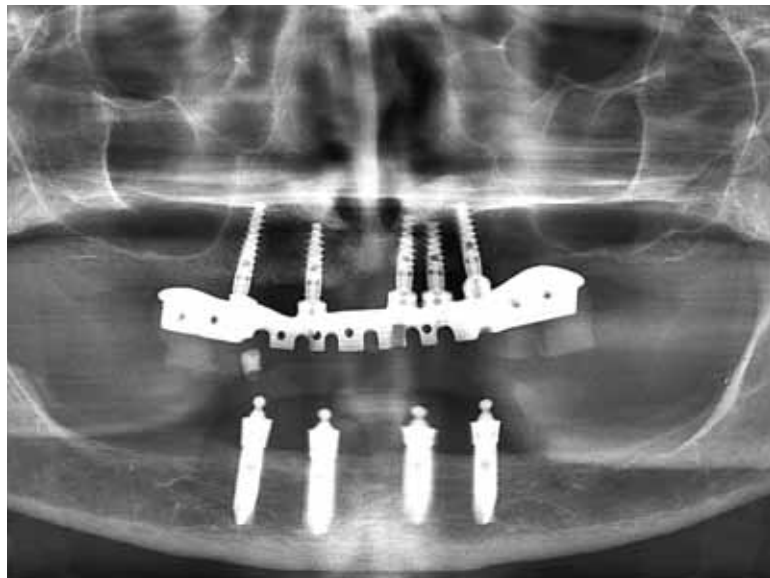
CAD CAM prosthesis on the master model



Prosthesis fitted in the mouth



Final restoration -
clinical view



1 year post
op panoramic
radiograph



Adin Dental Implant Sestems LTD
Industrial Zone Alon Tavor
POB 1128, Afula 1811101, Israel
Tel: +972-4-6426-732
Fax: +972-4-6426-733