



The Use of ULTRA NARROW PLATFORM 2.75mm Implants

Dr. **Adi Lorean**
Maxillofacial Surgeon

Case Studies

VOL. 3 | March 2017

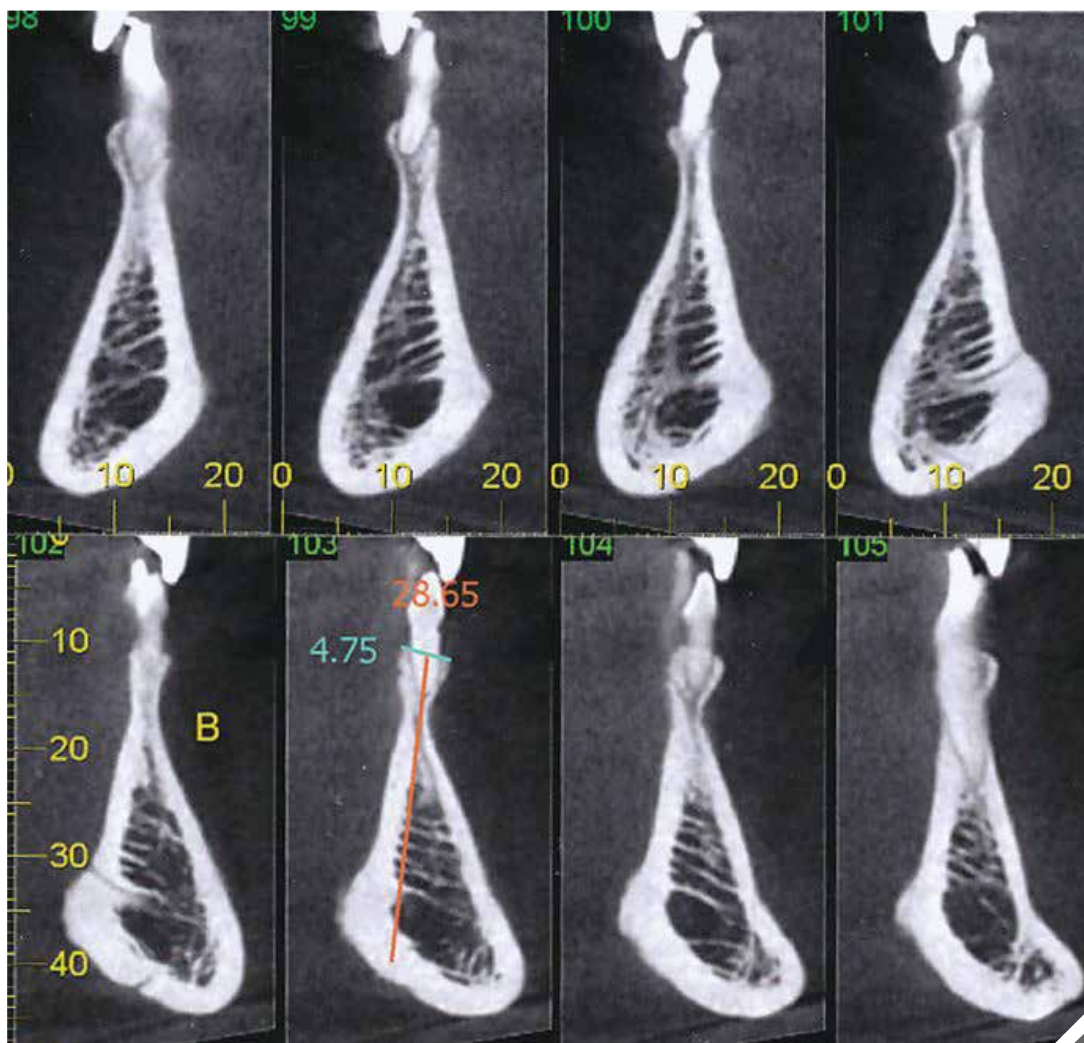


Restoration of Missing Permanent Anterior Incisors in the Mandible

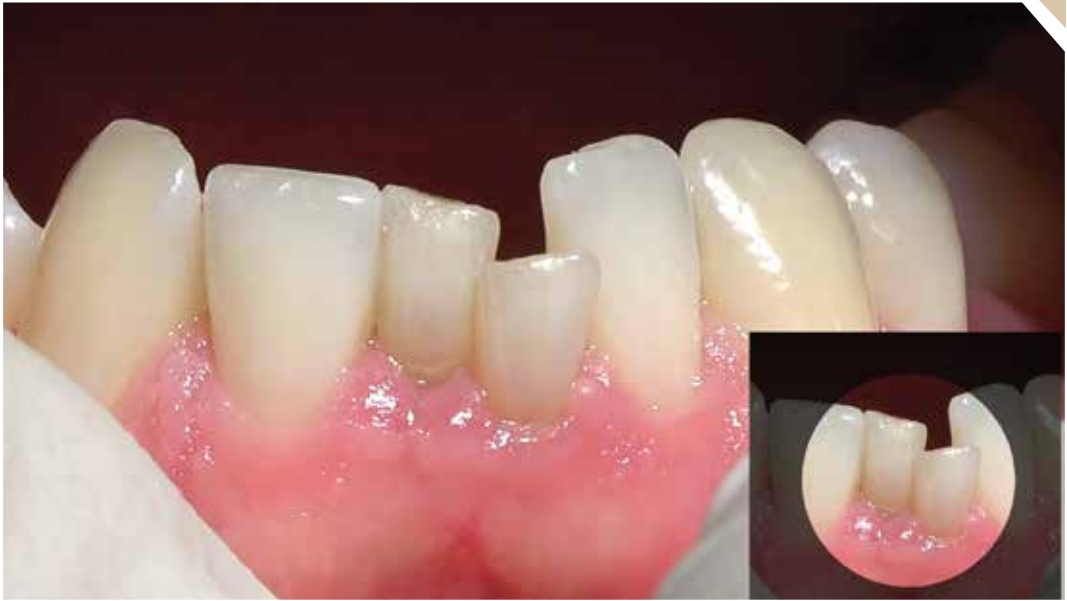A 24 years old patient, presented with partial anodontia of teeth 41 and 31. The deciduous teeth in the area presented with mobility class 2, crowded and discolored. The treatment plan consisted of extractions, immediate placement of one Adin CloseFit™ UNP 2.75 implant and immediate loading.

The immediate loading was performed on the same day and the patient was followed-up for 3 months. The x-ray and the clinical examination showed good implant stability and no bone loss, and he was referred for final restoration.

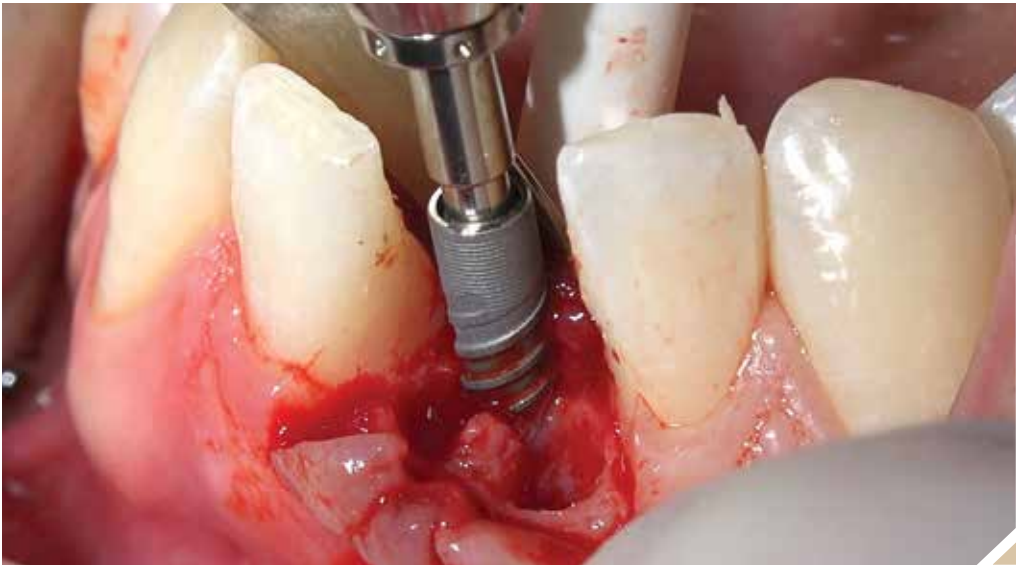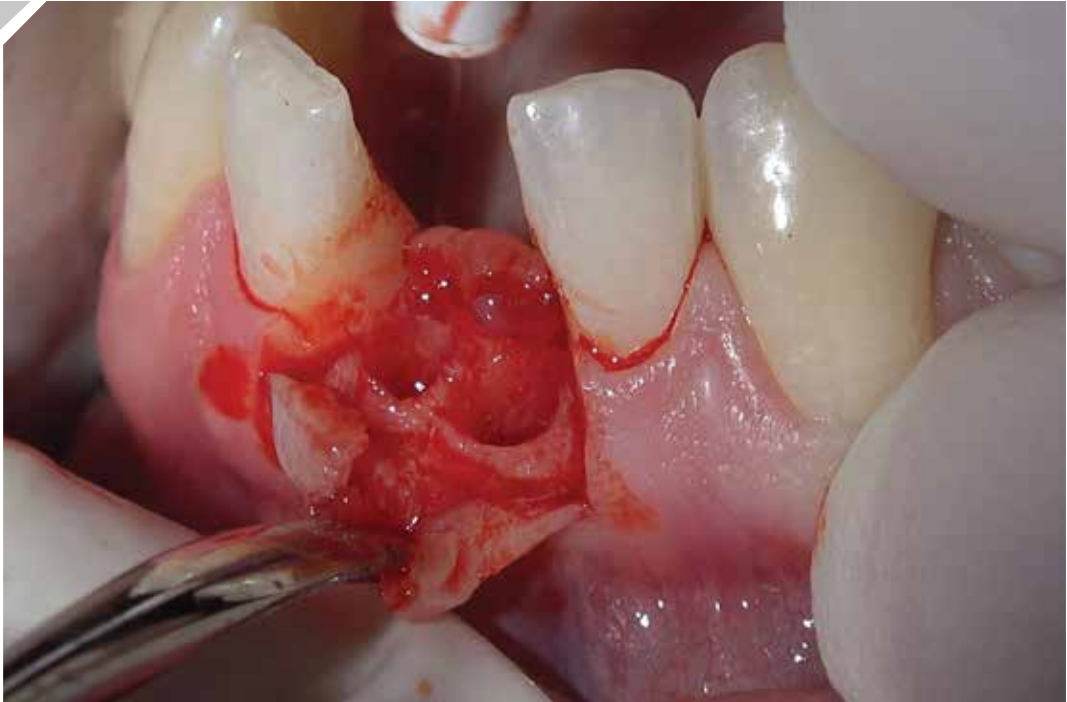Case 1



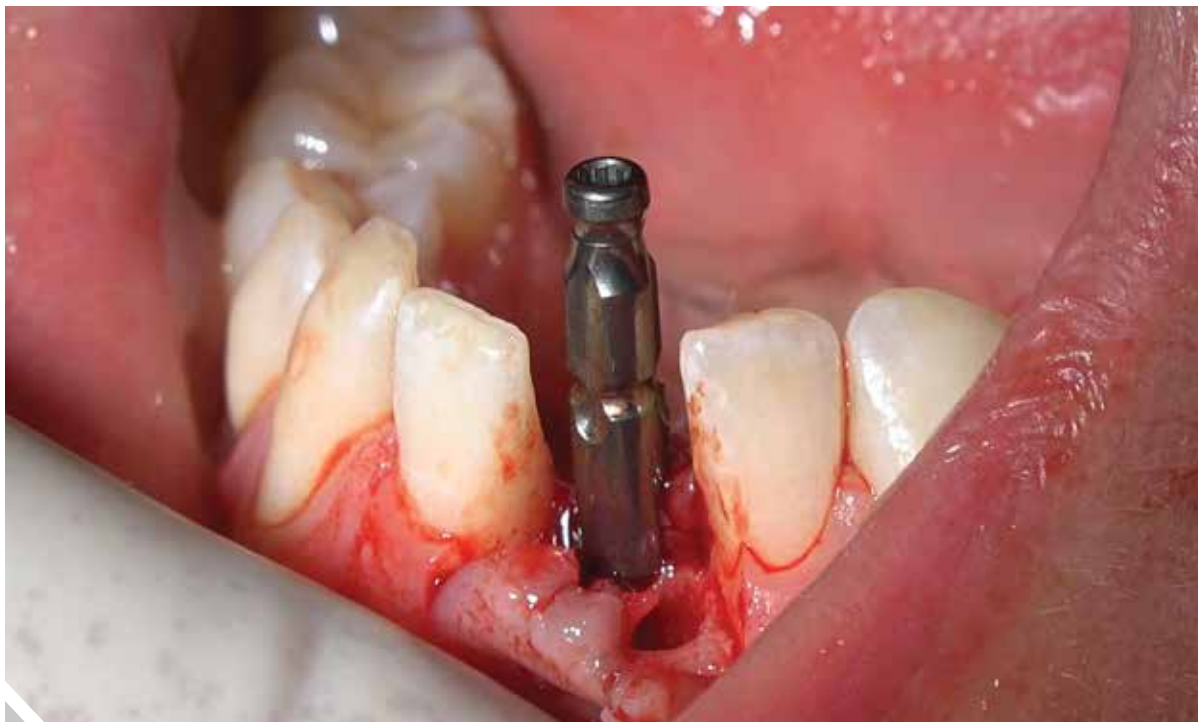Clinical picture of crowded deciduous teeth mandible 41 31 area



Extraction and full muco-periosteal flap elevation

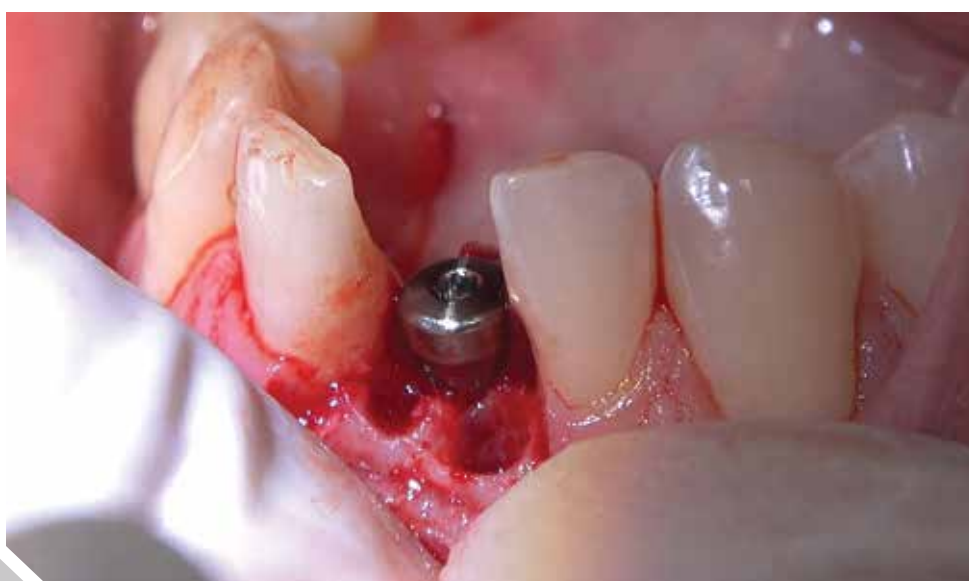

Positioning of the implant in the septa between the extracted teeth

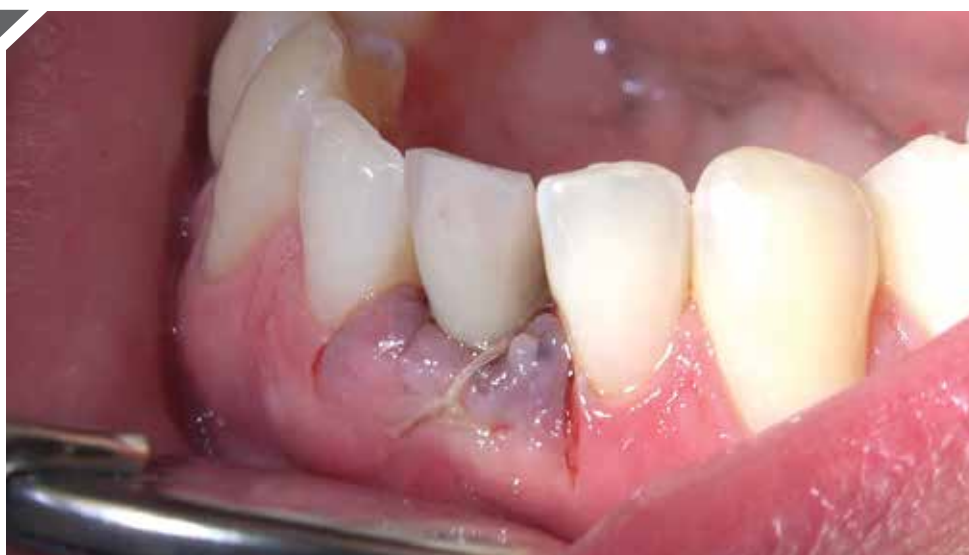

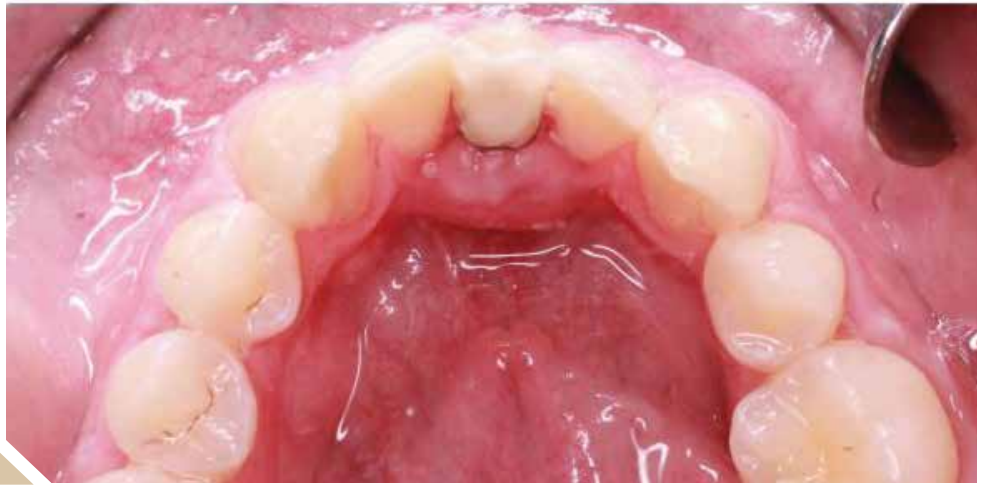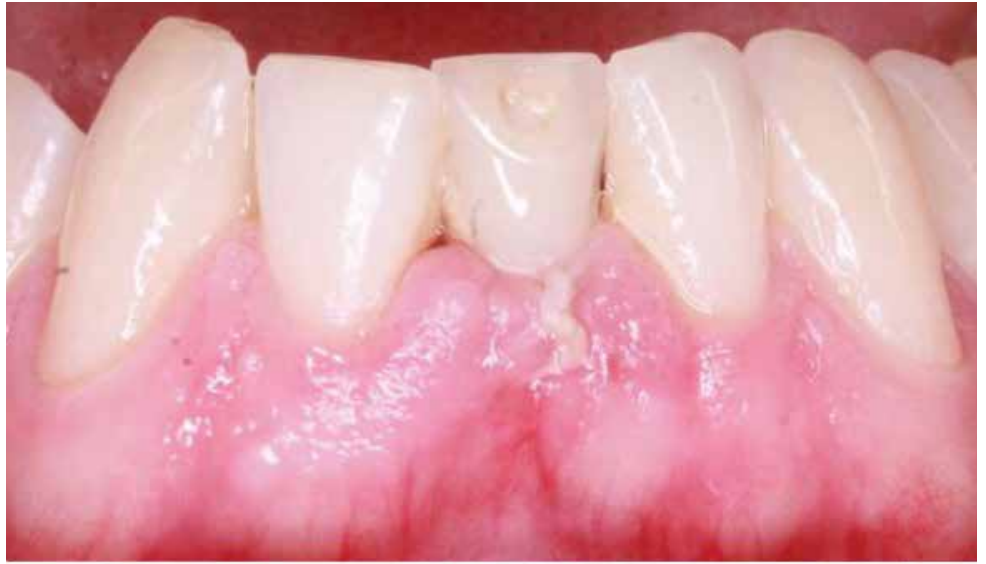UNP Transfer mounted for impression

Healing
abutment

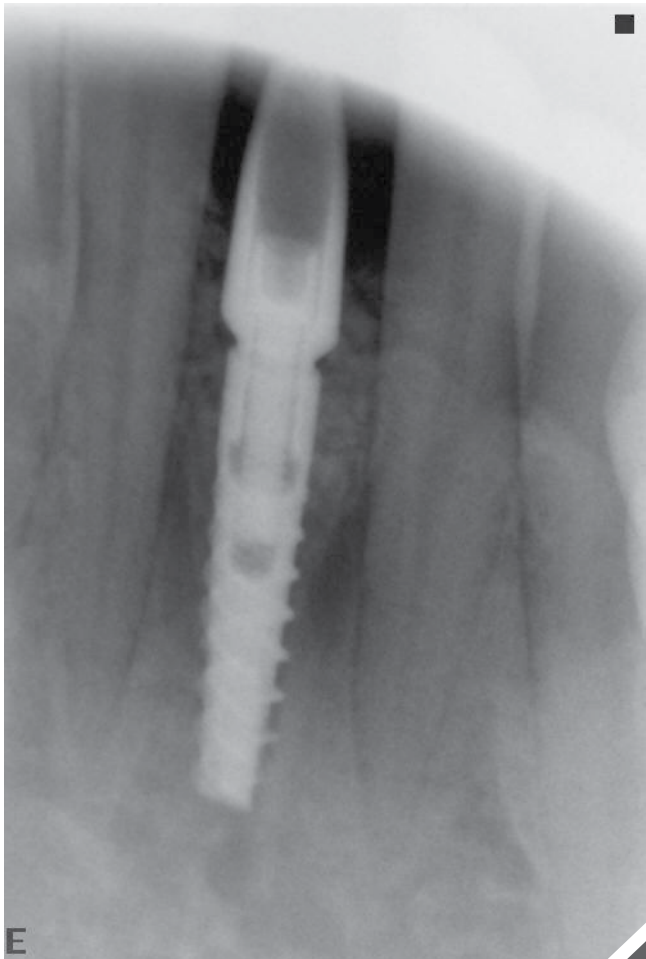


Immediate
loading with
temporary
acrylic crown





Immediate loading with temporary acrylic crown



One month post-op

E

Case 2

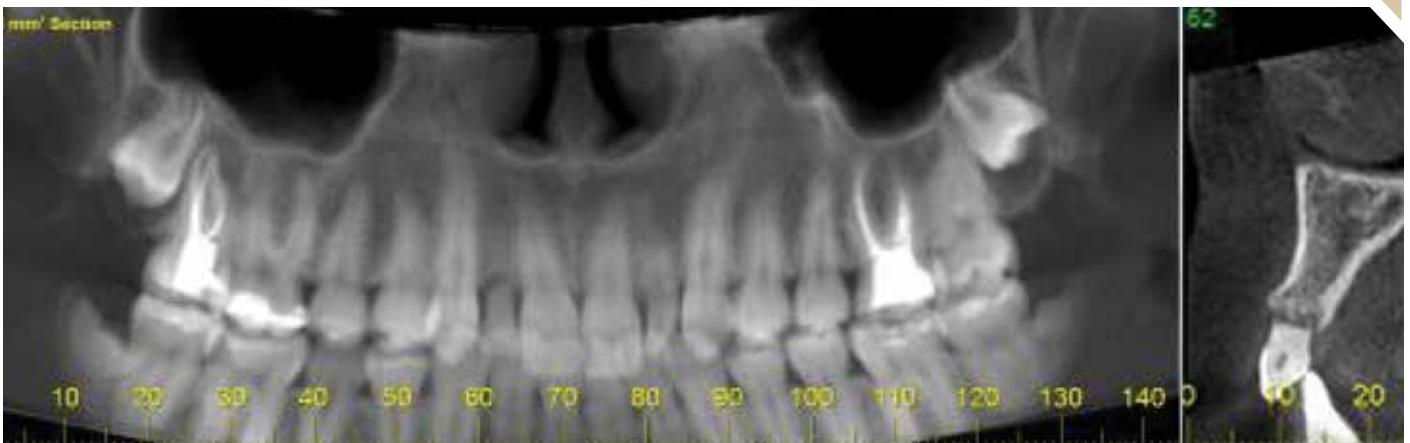
Restoration of Missing Permanent Upper Right Lateral Incisor

A 22 years old patient presented with partial anodontia of the upper right lateral incisor. The deciduous tooth presented with mobility class 3. The treatment plan consisted of extraction and immediate insertion of Adin CloseFit™ UNP 2.75 implant with a Maryland bridge for temporary rehabilitation. In this case, the deciduous tooth was used for the temporary bridge.

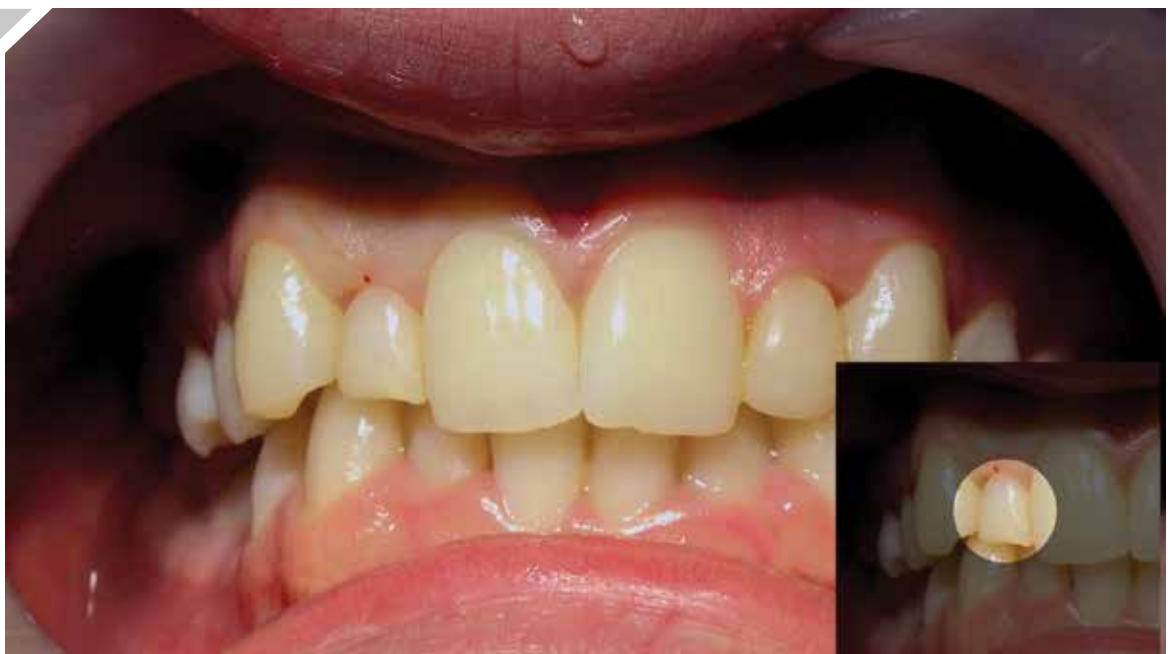Six months post-op impressions were taken for a ceramic crown cemented on a zirconia abutment.

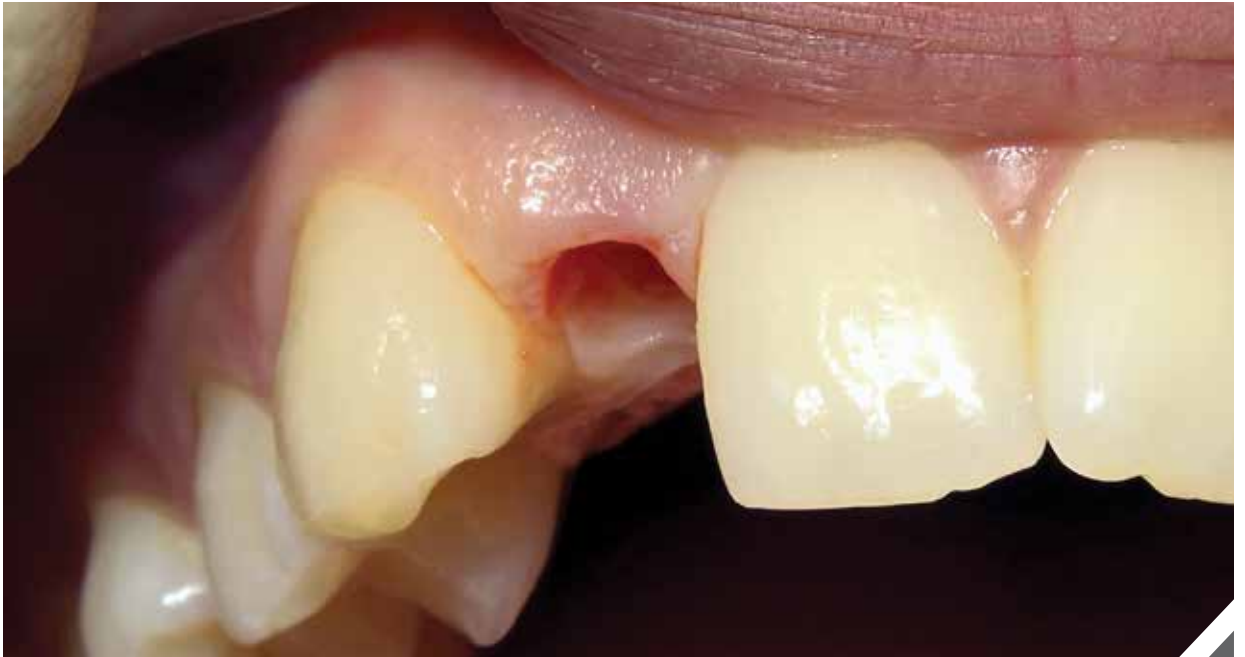Patient was satisfied and a one year follow-up x-ray and clinical examination revealed implant stability and good bone conservation around the implant.

Panoramic view



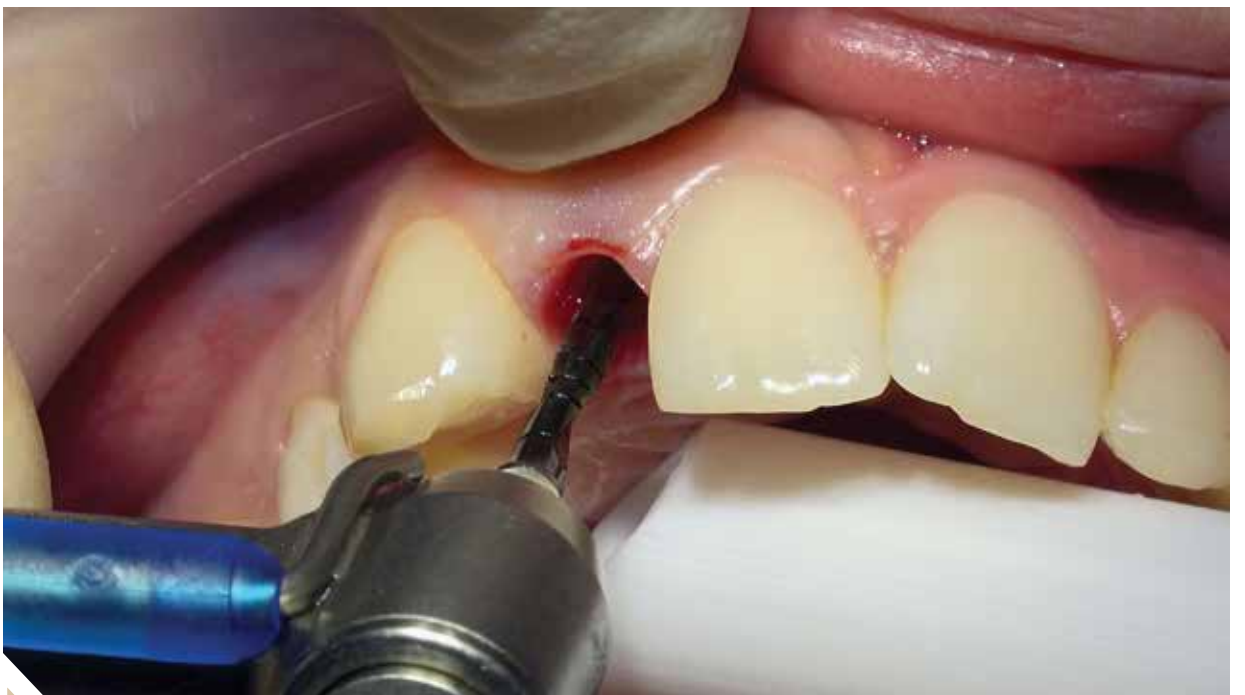Clinical image of the deciduous teeth and lack of width between the upper right incisor and the canine





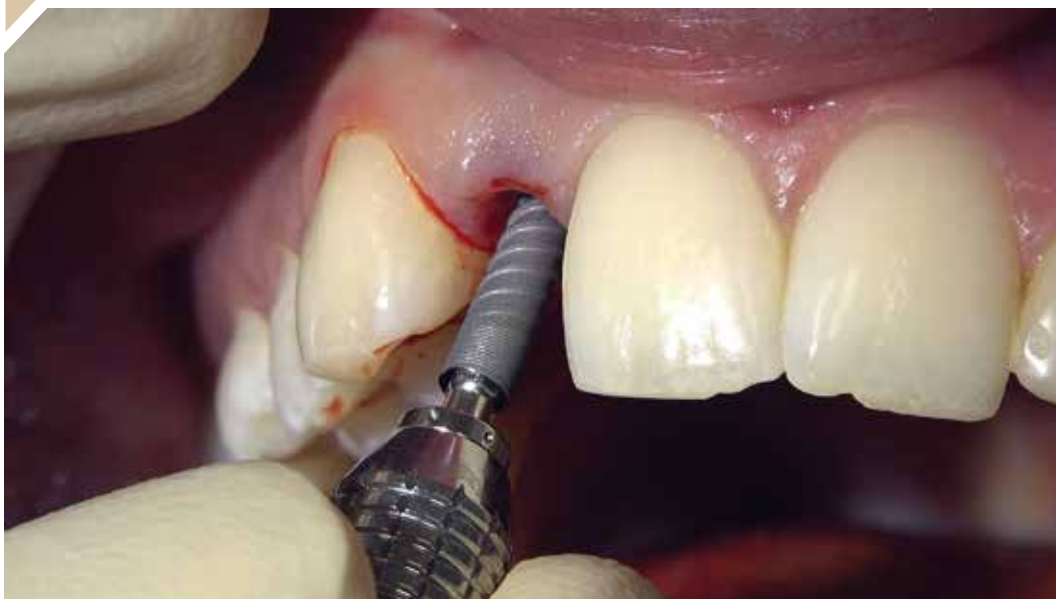Extraction of the deciduous tooth

LEAVE LIMITS BEHIND

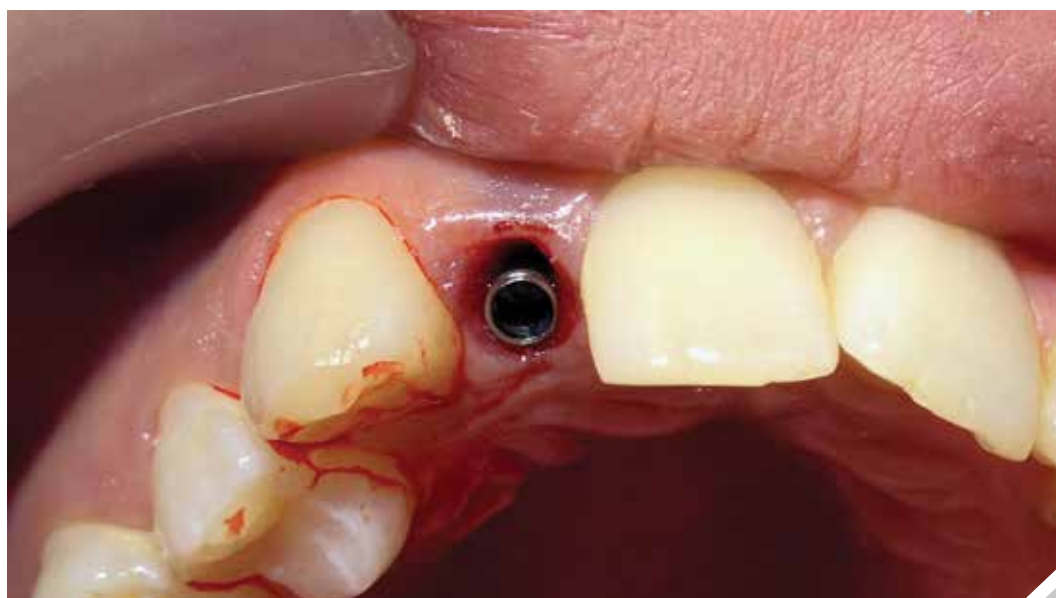


Osseotomy performed in the socket of the deciduous tooth

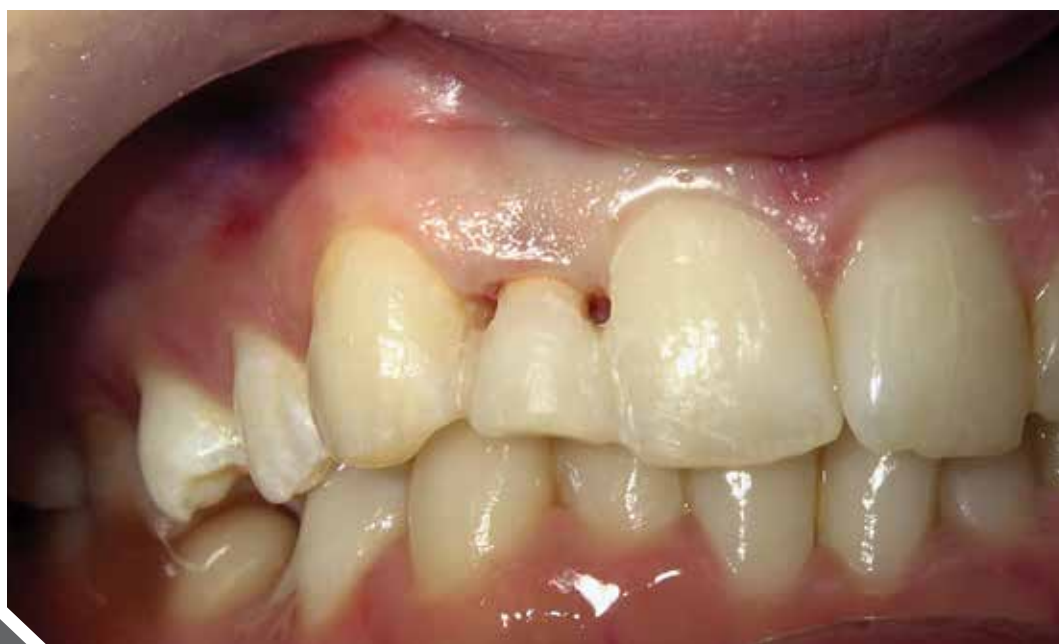Implant insertion



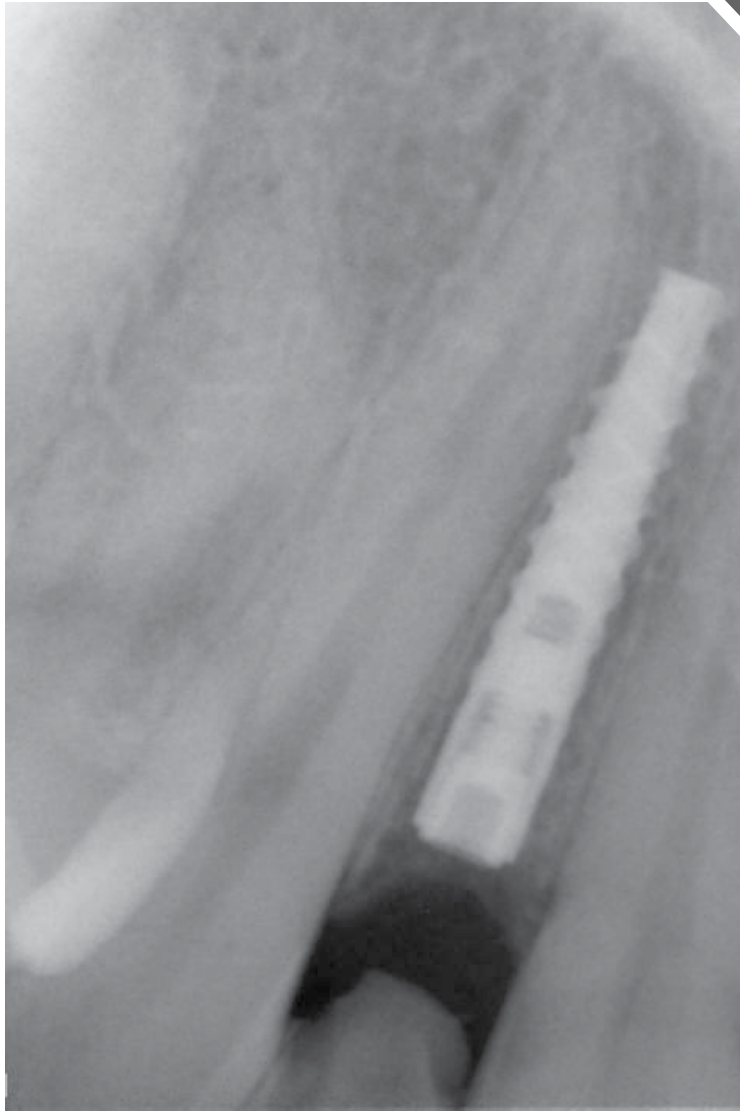
Evaluation of implant position in site



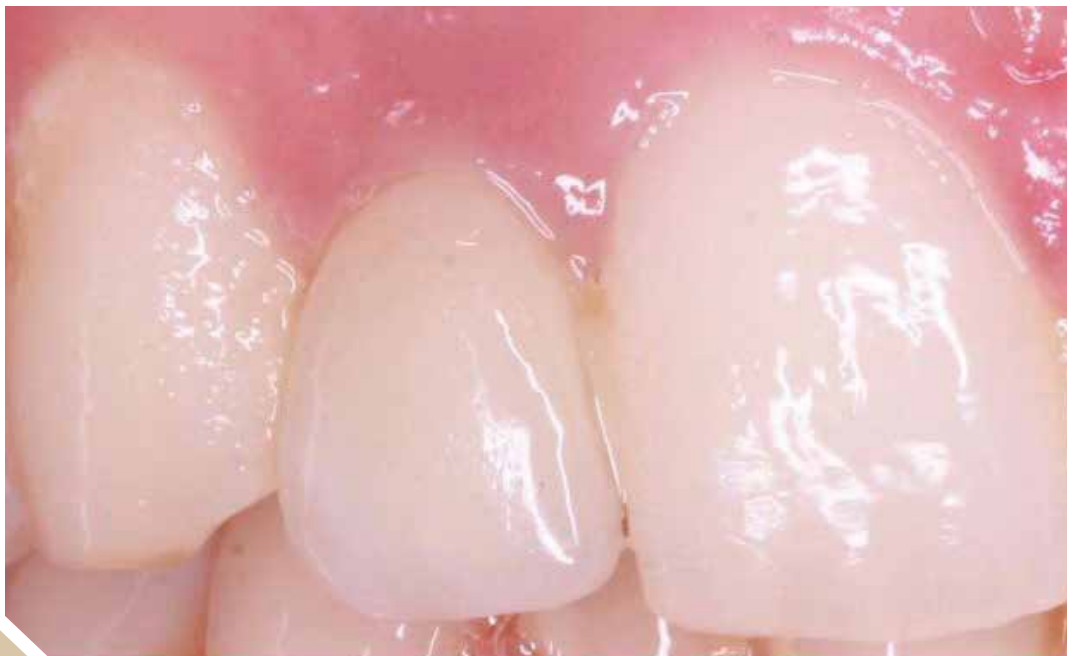Temporary Maryland bridge using the deciduous tooth



Six months follow-up



Final
restoration



Case 3

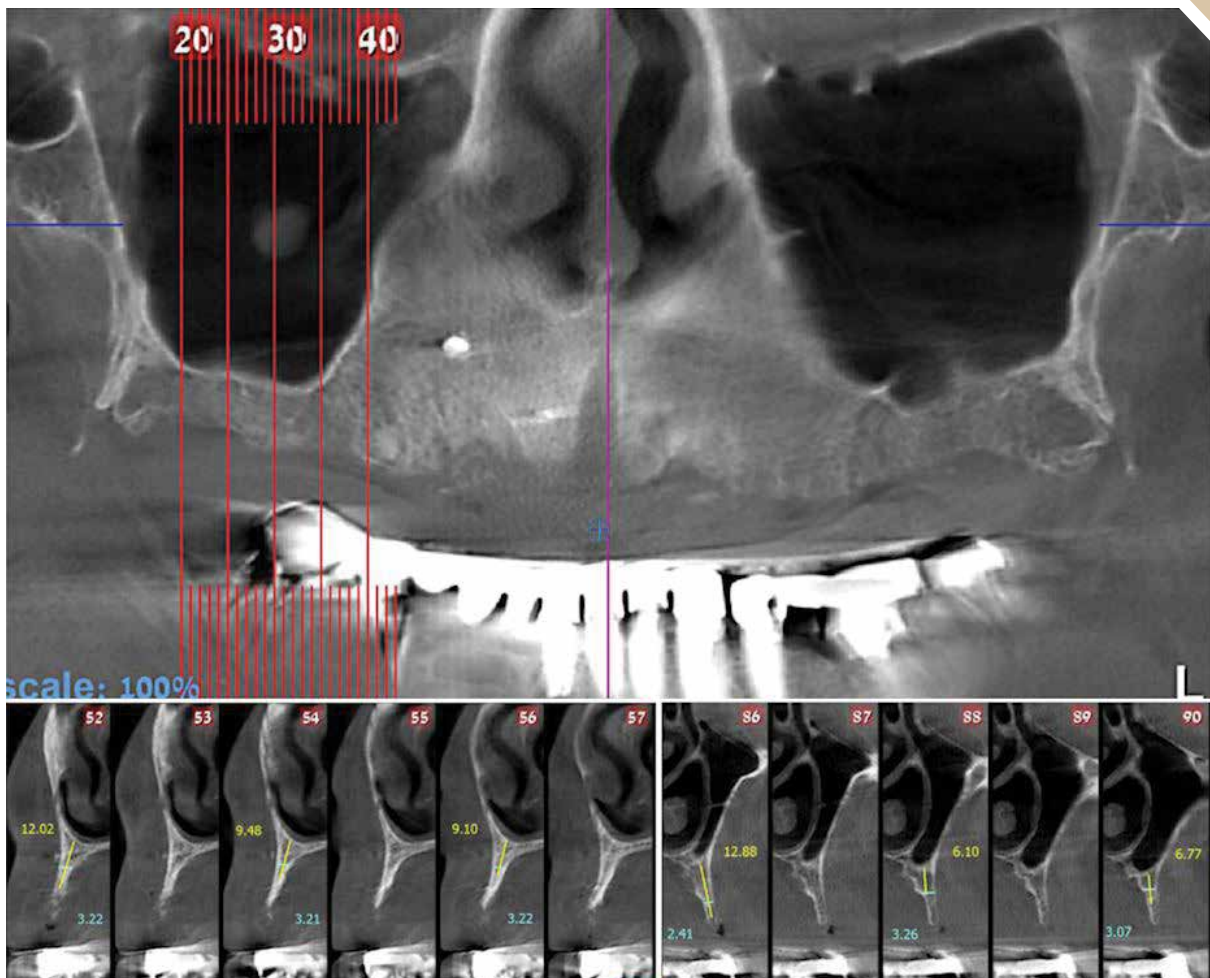
Upper Jaw Rehabilitation using an Implant Supported Denture

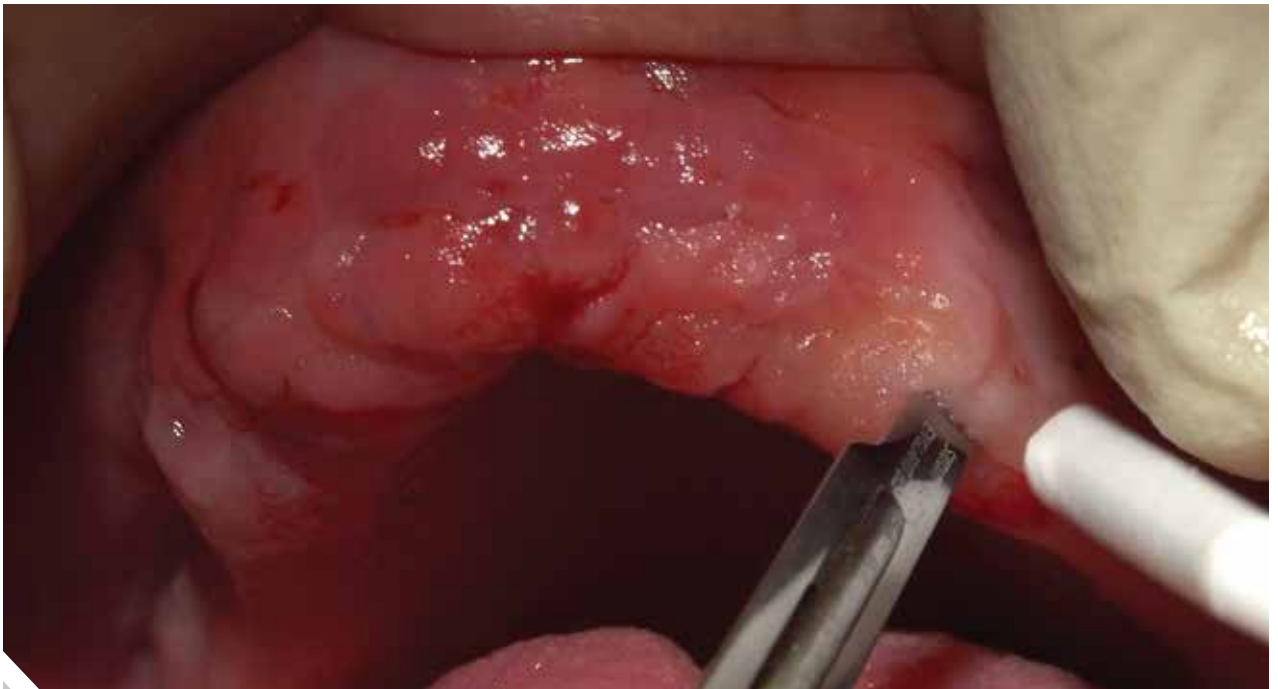A 51 years old patient presented with an edentulous upper jaw, wearing a full denture for almost 15 years, and a marked atrophy of the maxilla especially in buco-palatinal direction.

The treatment plan consisted of insertion of 4 Adin CloseFit™ UNP 2.75 implants in conjunction with bone augmentation and PRF.

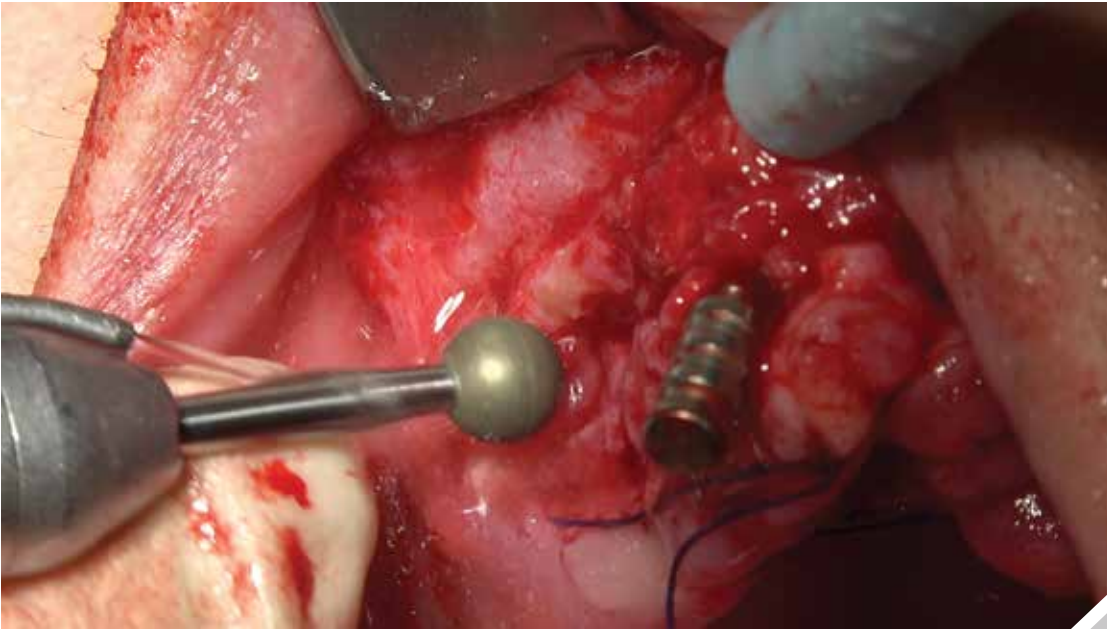
The patient was rehabilitated 8 months after the surgery with a removable denture supported by implants.

Panoramic view and CBCT

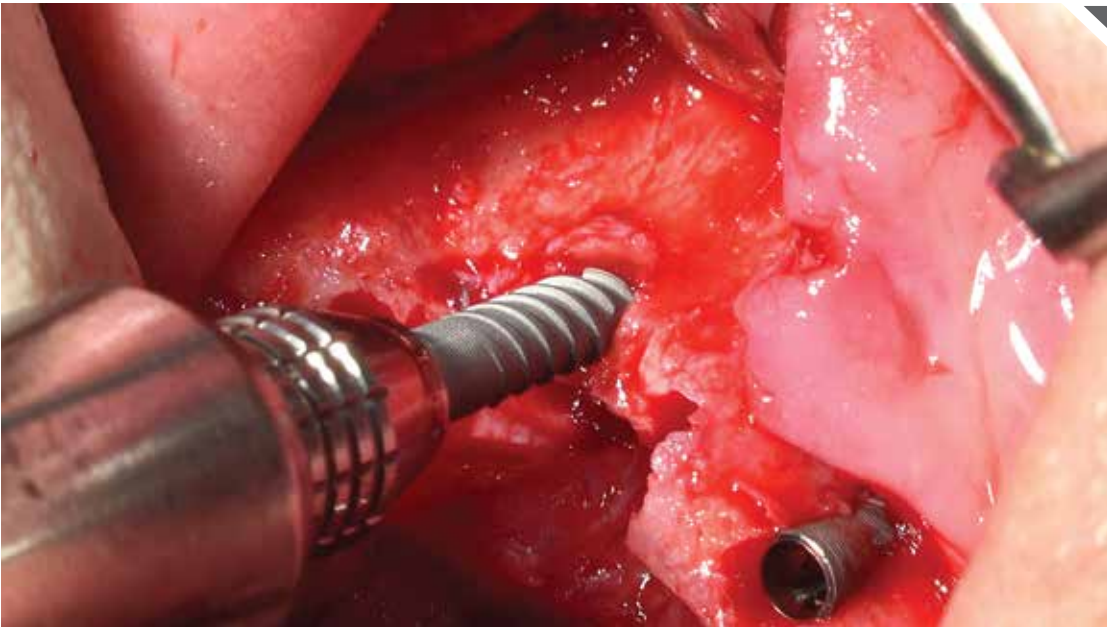




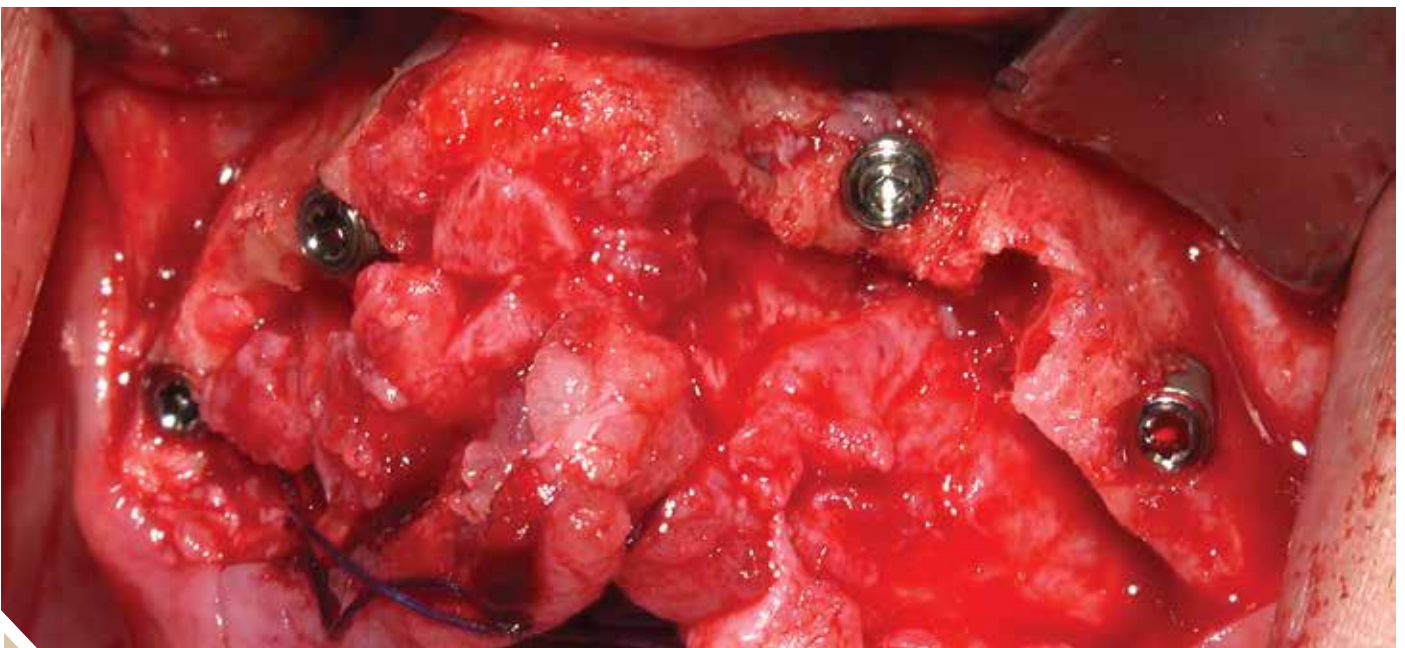
Muco-periosteal incision and flap elevation



Alveoplasty
of the ridge

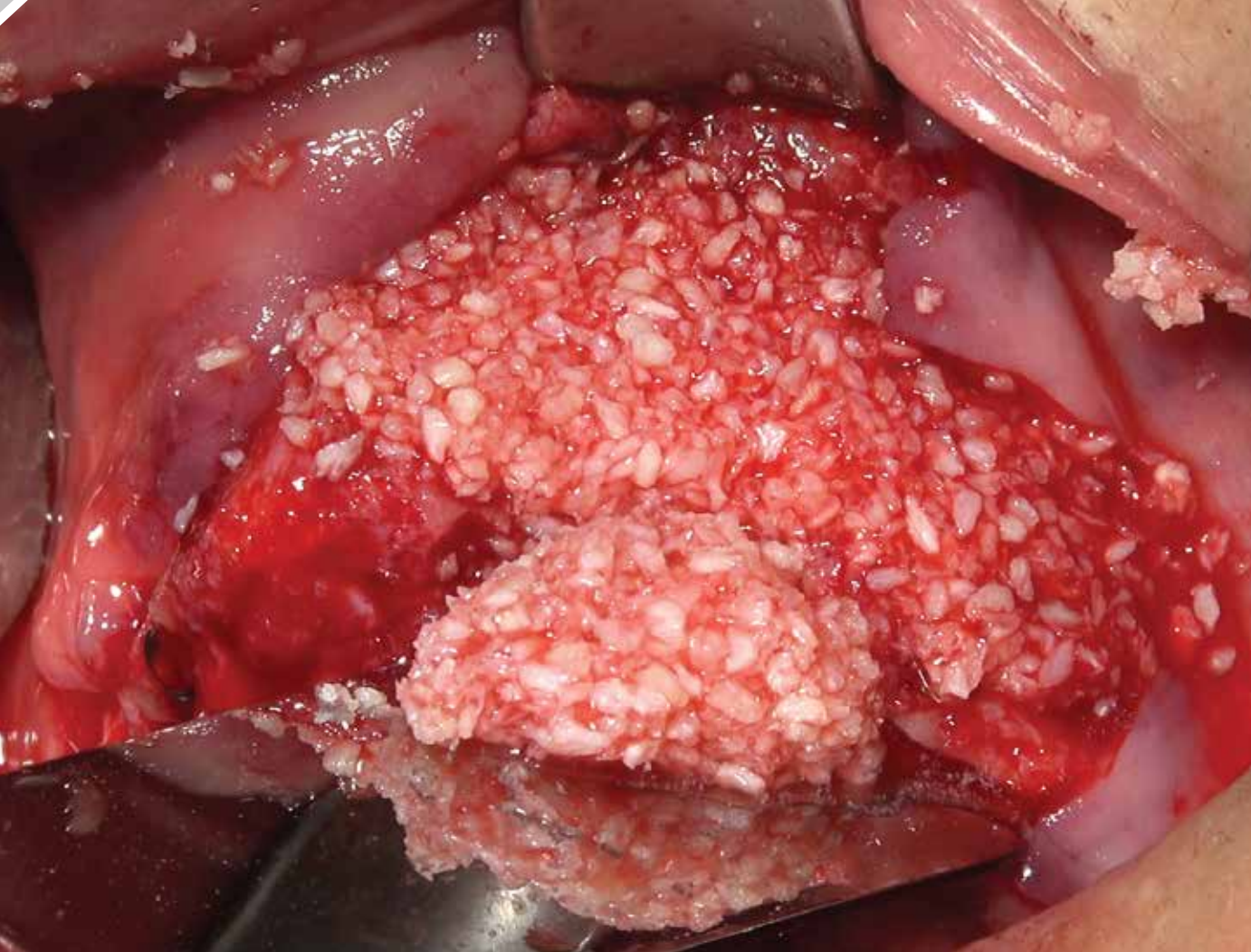


Implant
insertion

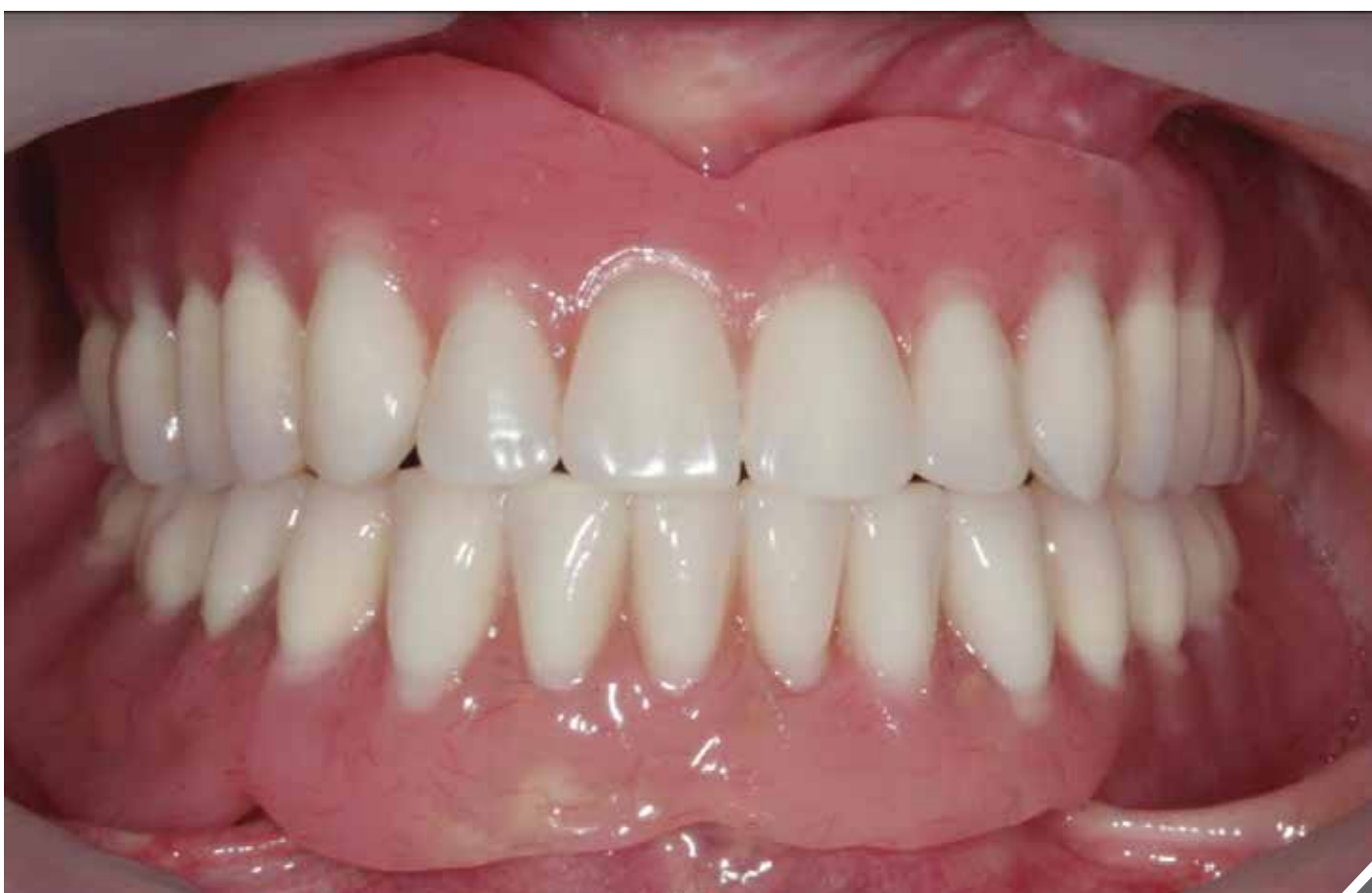
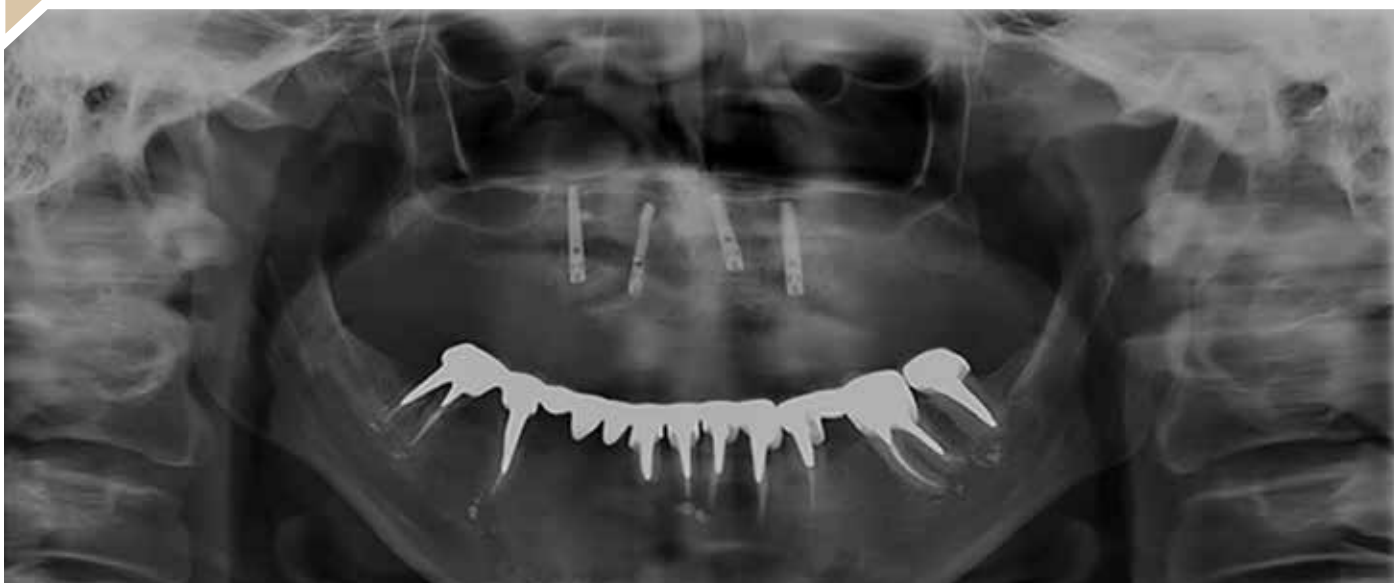
Clinical picture of the inserted implants

Bone augmentation and PRF



Final X-Ray six months post-op



Final restoration with a removable denture supported by four implants.
One year post-op

LEAVE LIMITS BEHIND

Acknowledgements:

Prosthetics by: **Dr. Andy Hod**

Lab work: **Mr. Alex Taran**

Images: **Roe Blenches - Dental Provideo**



Adin Dental Implant Systems LTD
Industrial Zone Alon Tavor
POB 1128, Afula 1811101, Israel
Tel: +972-4-6426-732
Fax: +972-4-6426-733